



IJPPR

INTERNATIONAL JOURNAL OF PHARMACY & PHARMACEUTICAL RESEARCH

An official Publication of Human Journals

ISSN 2349-7203




Human Journals

**Case Report**

January 2016 Vol.:5, Issue:2


© All rights are reserved by Dr.S.Parveen et al.

## Necrotizing Fasciitis: A Severe Bacterial Skin Infection



IJPPR  
INTERNATIONAL JOURNAL OF PHARMACY & PHARMACEUTICAL RESEARCH  
An official Publication of Human Journals

ISSN 2349-7203



**Dr.S.Parveen<sup>1</sup>, Bushrah Anjum.B<sup>2</sup>, Dr.Pallavipriya<sup>1</sup>,  
Venkata Subbaiah M<sup>1</sup>.**

<sup>1</sup> Assistant Professors, Department of Pharmacy  
Practice, P Rami Reddy Memorial College of Pharmacy,  
Kadapa, Andhra Pradesh, India (516003).

<sup>2</sup> Pharma D Interns, Department of general surgery,  
RIMS, Kadapa, Andhra Pradesh, India.

**Submission:** 9 January 2016  
**Accepted:** 15 January 2016  
**Published:** 25 January 2016



HUMAN JOURNALS

[www.ijppr.humanjournals.com](http://www.ijppr.humanjournals.com)

**Keywords:** Bacterial skin infection, Necrotizing fasciitis, bacterial skin infection

**ABSTRACT**

Necrotizing fasciitis (NF) is a speedily succeeding, inflammatory infection of the fascia through the secondary contribution of skin, subcutaneous tissues and muscle. NF is still remained a dreaded disease through towering morbidity and mortality due to quickly progressive necrotizing infection. Diabetes mellitus is one of the commonest jeopardy factors for the NF. There seems to be major relationship between progresses of NF and make use of non-steroidal anti-inflammatory (NSAID) drugs. It can affect any region or part of the human body. The main clinical suspicion of NF should happen when patient complaints of severe pain lopsided to the local injury. Common presenting sign and symptoms of NF are cruel pain, swelling and redness, Fever, hypotension. Local crepitus, blistering, local hypoesthesia or anesthesia. Reported every one of their NF patients had severe pain at the site of NF, 58% had tenderness and swelling while erythema was present. A 30 years old male complain of pain and itching in right lower limb since one month; patient was known hypertensive and is on tab. Atenolol [50mg] since one year. Upon investigation, the patient diagnosed to have cell necrosis of right lower limb [necrotizing fasciitis] and admitted in the male surgical department. The treatment was initiated with antibiotics and supportive medications to control the infection.

## INTRODUCTION

Necrotizing fasciitis (NF) commonly known as flesh-eating disease or flesh-eating bacteria syndrome is a rare infection of the deeper layers of skin and subcutaneous tissues. The majority of cases of necrotizing fasciitis are polymicrobial, with 25–45% of cases being Type II. The infection begins locally at a site of trauma, which may be severe (as the result of surgery).

People initially have signs of inflammation, fever and a fast heart rate. With progression of the disease, often within hours, tissue becomes progressively swollen; the skin becomes discolored and develops blisters. Crepitus may be present and there may be discharge of fluid, said to resemble "dish-water". Diarrhea and vomiting are also common symptoms. Mortality rates have been noted as high as 73 percent if left untreated <sup>[1]</sup>.

Diagnosis is confirmed by visual examination of the tissues and by tissue samples sent for microscopic evaluation <sup>[2]</sup>. Treatment for necrotizing fasciitis may involve an interdisciplinary care team. Bacteria coupled with necrotizing fasciitis include *Aeromonas species* [3]. *Aeromonas* organisms are Gram-negative small bacilli isolated from a diversity of environmental sources as well as water, seafood, meat and vegetables, with the ability to colonize both humans and animals. The clinical spectrum of *Aeromonas species* infection in humans include acute gastroenteritis, hepatobiliary tract infection, bacteremia, pneumonia, empyema, meningitis, endocarditis, septic arthritis, osteomyelitis, burn and wound infection [4].

Tissue biopsy is the gold standard for the diagnosis of NF, Laboratory jeopardy indicators for necrotizing fasciitis (LRINEC) score will diagnose NF near the commencement in emergency clinics. Pathophysiology of NF is rapid horizontal multiple of infection through facial necrosis and secondary vertical connection of skin.

Initial treatment often includes a combination of intravenous antibiotics including piperacillin/tazobactam, vancomycin, and clindamycin. Cultures are taken to determine appropriate antibiotic coverage, and antibiotics may be changed when culture results are obtained. Aggressive surgical debridement (removal of infected tissue) is always necessary to keep it from spreading and is the only treatment available. Maintaining strict asepsis during any surgical procedure and regional anesthesia techniques are vital in preventing the occurrence of the disease <sup>[5]</sup>.

## CASE REPORT

A 30 years old male patient was admitted in the male surgical department with the complaints of pain, itching and discharge of pus in right lower limb since one month; he was known hypertensive and is on regular medication with tab. Atenolol [50mg] since one year.

On initial examination, his lower limbs were warm in presence of erythema, swelling of his legs and progression of skin lesions (circumferential erythema developed in bulla formations), oozing of blood and pus from site of infections general condition of patient conscious and coherent, on physical examination blood pressure was 130/80, pulse rate 78 beat per minutes. Typical signs and symptoms include pronounced pain (allodynia), crepitus, watery discharge, oedema, skin blistering and cellulitis.

Upon microscopic evaluation, the patient was diagnosed as Necrotizing Fasciitis (cell necrosis of right lower limb) with discharge of pus. The treatment was started with antibiotics and supportive medications to control the infection. Antibiotics include Inj. Amoxicillin + clavulanic acid- 1.2gm two times a day, Inj. Amikacin 500mg two times a day, Inj. Metrogyl 100mg two times a day and supportive therapy includes Inj. Diclofenac -75mg two times a day, Inj. Pantop 40mg one time in a day. Same treatment was continued for 7 days. On day 8 patient complains of severe pain based on that complaint physician was added Inj. Tramadol 100mg. On 9<sup>th</sup> day patient condition got prognosis and was discharged with the following medication.

Rx:

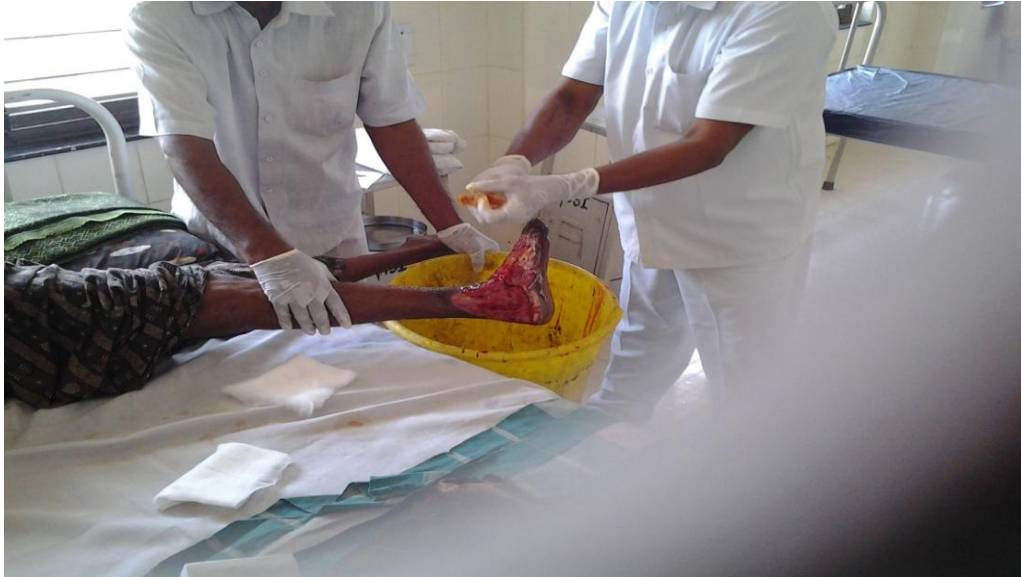Tab. Paracetamol -500mg-Three times in a day,

Tab. B-complex-67.5mg-Once in a day,

Tab. Vit-C -500mg- Once in a day,

Tab. Serratiopeptidase -10mg- Two times in a day.

The patient was counseled about the disease, medication and lifestyle modifications and was asked to review after 10 days. Necrotizing fasciitis is shown in figure-1.



**Figure 1: Patient with necrotizing fasciitis**

## DISCUSSION

NF is a disease that is predisposed by several risk factors, and whose outcome is based on early recognition and surgical treatment. Several studies demonstrated that diabetes mellitus and immunosuppressive therapy or bacterial skin infection. But in our case patient, NF developed may be because of hypertension or infection, in that report patient not having any abnormal past or present medical, medication condition.

NF generally associated with bacteria which include *Aeromonas species*. *Aeromonas* organisms are Gram-negative small bacilli isolated from a variety of environmental sources including water, seafood, vegetables and meat, with the ability to colonize both animals and humans. The clinical spectrum of *Aeromonas species* infection in humans includes acute gastroenteritis, hepatobiliary tract infection, pneumonia, empyema, meningitis, septic arthritis, osteomyelitis, endocarditis, bacteremia, burn and wound infection.

85% of clinical isolates human infections engage three phenotypically defined species, *Aeromonas caviae*, *Aeromonas hydrophila* and *Aeromonas veronii biovar sobria*. *A. veronii biovar sobria* is more pathogenic than *A. hydrophila* and it is mainly isolated in patient's blood.

*Aeromonas bacteremia* possible portals of entry are skin lesions, gastrointestinal tracts, local trauma, and previous surgery. After adhesion to epithelial cells, it produces many virulent factors which destroy impair immune cells and host epithelial barriers, including cytotoxic exoenzymes, and cytotoxic enterotoxins, proteinases, hemolysins, lipases, agglutinins, various hydrolytic enzymes, translocation capacity and *Aeromonas sobria* cytotoxic factor. *Aeromonas* infections can develop in healthy and trauma patients but immunocompromised hosts with hematologic malignancy, cancer and hepatobiliary diseases are considered to be at greatest risk [6].

NF commonly known as flesh-eating disease or flesh-eating bacteria syndrome is a rare infection of the deeper layers of skin and subcutaneous tissues. The most consistent feature of necrotizing fasciitis was necrosis of the subcutaneous tissue and fascia with relative sparing of the underlying muscle [7].

Patients with severe wound infection (myonecrosis) caused by this microorganism also develop sepsis, and 90% of patients succumb to their infections. The fatality rate of *Aeromonas* soft tissue infections and bacteremia is high and reportedly ranges from as much as 28% to 73%, with septic shock being the cause of death in the majority of patients [8].

## CONCLUSION

NF is a disease with a high probability of mortality, which is compounded by several additional risk factors. Early detection and surgical debridement, as well as aggressive antimicrobial therapy is essential to limit loss of limb or life. Several complicating factors contributed to the loss of limb in this case. Early detection and diagnosis were hindered by diabetes and immunosuppressive therapy. Nonetheless, the patient survived this life-threatening episode due to aggressive surgical and medical management.

Previous studies concluded that major factors can enhance the NF due to the usage of immunosuppressant, Nonsteroidal anti-inflammatory drugs, Diabetes mellitus and Bacterial infections. But in this case, NF developed may be for the reason that of infections as well as hypertension.

It is a severe disease of sudden onset and is usually treated immediately with surgical debridement and large doses of intravenous antibiotics; higher mortality is being associated with

delay in surgical treatment. In this case, recommended that cultures are taken to determine appropriate antibiotic coverage and antibiotics may be changed when culture results are obtained.

### **ACKNOWLEDGEMENTS**

The authors would like to express their sincere thanks to staff and students of department of Pharmacy Practice, P Rami Reddy Memorial College of Pharmacy, and Kadapa and to the Physicians and Nurses, Department of surgery, Rajiv Gandhi Institute of Medical Sciences, Kadapa, India.

### **CONFLICT OF INTERESTS**

The authors have declared that they have no conflict of interest.

### **REFERENCES**

1. Accessed on: <http://dx.doi.org/10.4236/ss.2012.311103> Published Online November 2012 <http://www.SciRP.org/journal/ss>.
2. Accessed on: <http://www.jmedicalcasereports.com/content/8/1/315#B3>.
3. Accessed on: <http://www.jmedicalcasereports.com/content/8/1/315#B4>.
4. Wilson, B. Necrotising Fasciitis. *Am Surg* 1952; 18 (4): 416–31.
5. Sarani, Babak et al., Necrotizing Fasciitis: Current Concepts and Review of the Literature. *Journal of the American College of Surgeons* 2009; 208 (2): 279–288.
6. Accessed on: <http://www.jmedicalcasereports.com/content/8/1/315#B12>.
7. Dr. Chris Suykerbuyk, DPM1, Dr. Robert Frykberg. Necrotizing Fasciitis: A case report, *The Journal of Diabetic Foot Complications*; 2010; 2; 1: 1.
8. Accessed on: <http://www.jmedicalcasereports.com/content/8/1/315#B13>.