



IJPPR

INTERNATIONAL JOURNAL OF PHARMACY & PHARMACEUTICAL RESEARCH  
An official Publication of Human Journals

ISSN 2349-7203




Human Journals

Research Article

July 2016 Vol.:6, Issue:4


© All rights are reserved by A.Rajani et al.

# Hepatoprotective Activity of Methanolic Leaf Extract of *Indigofera barberi* Gamble against Paracetamol Induced Hepatotoxicity in Rats



IJPPR  
INTERNATIONAL JOURNAL OF PHARMACY & PHARMACEUTICAL RESEARCH  
An official Publication of Human Journals

ISSN 2349-7203



**<sup>1</sup>A.Rajani, <sup>2</sup>A.Jaswanth**

*<sup>1</sup>Ph.D Research Scholar, Pacific Academy of Higher Education and Research, <sup>2</sup>Profesoor & Principal, Procadence Institute of pharmaceutical Sciences, India.*

**Submission:** 7 July 2016  
**Accepted:** 12 July 2016  
**Published:** 25 July 2016

**Keywords:** *Indigofera barberi* Gamble Biochemical markers, Hepatoprotective & Hepatotoxicity, Paracetamol, Methanolic leaf extract, Silymarin

## ABSTRACT

The present study, the methanol extract of *Indigofera barberi* Gamble leaf was evaluated for their protective effects on paracetamol-induced liver damage in Wistar albino rats. Serum biochemical parameters viz. aspartate aminotransferase (AST), alanine transaminase (ALT), alkaline phosphatase (ALP), total protein, bilirubin, cholesterol, albumin (ALB), lactate dehydrogenase (LDH), triglycerides; and liver biochemical parameters such as reduced glutathione (GSH) content and catalyses (CAT) and superoxide dismutase (SOD) activities were evaluated. Paracetamol (500mg/kg) induces hepatotoxicity and enhances the ALT, AST, ALP, liver weight and reduces total proteins. Treatment with Methanolic leaf extract of *Indigofera barberi* Gamble (200mg/kg & 400mg/kg) has brought back the altered levels of biochemical markers significantly to the near normal levels. The results were supported by histopathological studies of liver tissue. Phytochemical analysis of *Indigofera barberi* Gamble indicated the presence of alkaloids, phenolics, saponins, flavonoids and polysaccharides. The study concluded that the hepatoprotective potential may be attributed to the presence of flavonoids.



[www.ijppr.humanjournals.com](http://www.ijppr.humanjournals.com)

## INTRODUCTION

The liver is the vital organ of paramount importance involved in the maintenance of metabolic function and detoxification from the exogenous and endogenous challenges, like xenobiotic, drugs, viral infection and chronic alcoholism<sup>1</sup>. If during all such exposures to the above mentioned challenges the natural protective mechanisms of the liver are overpowered, the result is hepatic injury. Liver damage is always associated with cellular necrosis, increase in tissue lipid peroxidation and depletion in the tissue GSH levels. In addition serum levels of many biochemical markers like AST, ALT, ALP and bilirubin are elevated<sup>2</sup>.

Herbs play a major role in the management of various liver disorders along with other system associated diseases. Hepatotoxicity is very common ailment resulting in serious debilities ranging from severe metabolic disorders to even mortality<sup>3</sup>. Plant derived natural products such as flavonoids, terpenoids and steroids have received considerable attention in recent years due to their diverse pharmacological properties including antioxidant and hepatoprotective activity<sup>4,5</sup>.

Herbal medicines are known to play an important role in the treatment of various elements including liver disorders and many traditional practitioners have claimed that numerous medicinal plants can be extensively used for the alleviation of different types of liver disorders<sup>6</sup>. In spite of phenomenal growth of modern medicine there are no synthetic drugs are available for the treatment of hepatic disorders. However, there are several herbs/herbal formulation claimed have possess beneficial activity in treating hepatic disorders.

*Indigofera barberi* Gamble is a class of dicotyledons plant belonging to the family Fabaceae. It is distributed in the deciduous forests of Chittor district. It is an erect plant under shrub. The leaves are about 20-26mm long and 6-12mm wide, oblong and ovate to lanceolate, base with a short petiole<sup>7</sup>. Entire plant including the flowers of this plant is well known in treating various liver disorders and renal disorders<sup>8</sup>.

## MATERIALS AND METHODS

### Animals:

Male Wistar rats weighing between 150-220gms were used for this study. The animals were obtained from National Institute of Nutrition (NIN), Hyderabad, India. The animals were placed

at random and allocated to treatment groups in polypropylene cages with paddy husk as bedding. Animals were housed at a temperature of  $24\pm 2^{\circ}\text{C}$  and relative humidity of 30-70%. A 12:12 light: day cycle was followed. All animals were allowed to free access to water and fed with standard commercial pelleted rat chaw. All the experimental procedures and protocols used in this study were reviewed by the Institutional animal ethics committee and were in accordance with the guidelines of CPCSEA.

### **Plant Material:**

Leaves of *Indigofera barberi* Gamble was collected from Seshachalam hills and authenticated by Dr. K. Madhava Chetty, Assistant Professor in Department of Botany, Sri Venkateshwara University, Tirupati, Chittoor district, Andhra Pradesh.

The leaves were dried under shade and powdered mechanically to coarse powder. The coarsely powdered leaf material was subjected to hot continuous extraction process in a soxhlet apparatus using methanol as solvent. The extract was evaporated to semisolid mass and subjected to preliminary phytochemical investigation.

The extract obtained was greenish brown colour and soft in nature. The percentage yield was approximately 6% w/w. The methanolic extract was tested for the presence of various phytochemical constituents. The methanolic extract of *Indigofera barberi* Gamble was found to contain alkaloids, carbohydrates, glycosides, phytosterols, saponins, tannins, amino acids, flavonoids and di-terterpenes through literature<sup>9</sup>.



**Fig: 1. Leaves of *Indigofera barberi* Gamble**

**Animals:**

Healthy adult male Wistar Albino rats of 180-250gms were selected for the study. The animals were obtained from National Institute of Nutrition (NIN), Hyderabad. The animals were housed according to CPCSEA guidelines (under standard temperature condition). They were given a pellet diet and water ad libitum. The ethical clearance was obtained from Institutional Animal Ethics Committee (IAEC) before the experiment.

**Acute toxicity studies (OECD 423):**

An acute toxicity study was performed on methanol extract following OECD guidelines (423). The dosage for the pharmacological studies was selected as 1/10th of the highest dose (4000 mg/kg) administered.

**Experimental design:**

**Paracetamol induced Hepatotoxicity**

In this study, adult male Wistar Albino rats of 180-250gms were taken. A total of 30 animals were equally divided into 5 groups of six each. Group-1 served as normal control received 1% tween-80 (1ml/kg) once daily for 3 days. Group-2 served as paracetamol control, administered with paracetamol (500mg/kg) as single dose on day 3. Group-3 served as reference control which received silymarin (25mg/kg) once daily for 3 days. Group-4 received test extract methanolic leaf extract of *Indigofera barberi* Gamble (200mg/kg) once daily for 3 days Group-5 received test extract, methanolic leaf extract of *Indigofera barberi* Gamble (400mg/kg) once daily for 3 days. Group- 3, 4 & 5 received paracetamol (3gm/kg) as single dose on day 3, thirty minutes after the administration of the test extract and silymarin respectively. The test extract and paracetamol were administered orally by suspending in 1% tween-80 solution. After 7 days of paracetamol feeding, the blood was collected by retro-orbital artery bleeding under light ether anaesthesia and serum was separated for the estimation of liver biochemical parameters<sup>10</sup>.

**Body Weight and Liver Weights:** The body weight of rats of each group were measured just before and 7 days after treatment. Liver weights of all rats were measured after post treatment sacrifice.

**Serum Biochemical Parameters:** The collected blood was used for the estimation of serum biochemical parameters viz. serum glutamate oxaloacetate transaminase (AST), serum glutamate pyruvate transaminase (ALT), serum alkaline phosphatase (SALP), total bilirubin, total cholesterol, TP, ALB, triglycerides, and LDH.

**Liver Biochemical Parameters:** The liver biochemical parameters Such as reduced glutathione (GSH) content and catalase (CAT) and SOD activities were evaluated.

**Statistical analysis:**

All the values were expressed as mean  $\pm$  SEM. The data was statistically analyzed by one way analysis of variance (ANOVA) followed by Dunnett's 't'-test and values  $p < 0.05$  were considered to be significant.

**RESULTS**

**Preliminary Phytochemical:**

The results of the preliminary phytochemical screening of *Indigofera barberi* Gamble the methanolic extracts reveals the presence of phytoconstituents such as alkaloids, flavonoids, Steroids carbohydrates, glycosides, phytosterol, saponins, tannins and diterpenes and represent in the Table No.1.

**Table No.1: Phytochemical investigation of *Indigofera barberi* Gamble Methanolic leaf extract**

S.No.	Constituents	Report
1	Carbohydrates	+
2	Steroids	++
3	Alkaloids	+
4	Flavonoids	++
5	Glycosides	+
6	Proteins	-
7	Tannins	+
8	Volatile Oils	+

+ Presence, - absent

### **Acute toxicity studies:**

Administration of *Indigofera barberi* Gamble leaf extract in the dose of 50, 300 & 4000 mg/kg resulted in no mortalities or evidence of adverse effects implying that *Indigofera barberi* Gamble is nontoxic. Throughout 14 days of the treatment no changes in behavioral pattern, clinical signs and body weight of mice in both control and treatment groups were observed. This shows that *Indigofera barberi* Gamble was safe up to a dose of 4000mg/kg.

### **Hepatoprotective activity**

The results of hepatoprotective activity of methanolic extract of *Indigofera barberi* Gamble on paracetamol induced liver injury in rats with reference to biochemical changes in serum are given Table. No. 2, 3 and 4. Histological profile of animals is depicted in figure.1,2,3and 4 at the end of the study the treatment blood samples of paracetamol treated animals showed significant increase in the levels of total bilirubin, alanine aminotransferase, aspartate aminotransferase, alkaline phosphatase, lactate dehydrogenase, cholesterol and triglyceride compared to the normal control group, but the total protein level decreased reflecting the liver injury caused by paracetamol; whereas blood samples from the animals treated with root extract of *Indigofera barberi* Gamble at the dose 200mg/kg was very less significant and 400mg/kg body weight showed significant decrease in the levels of serum markers and significant increase in the total protein to the near normal value which are comparable to the values registered in the standard drug treated group of animals, indicating the protection of hepatic cells against paracetamol damage.

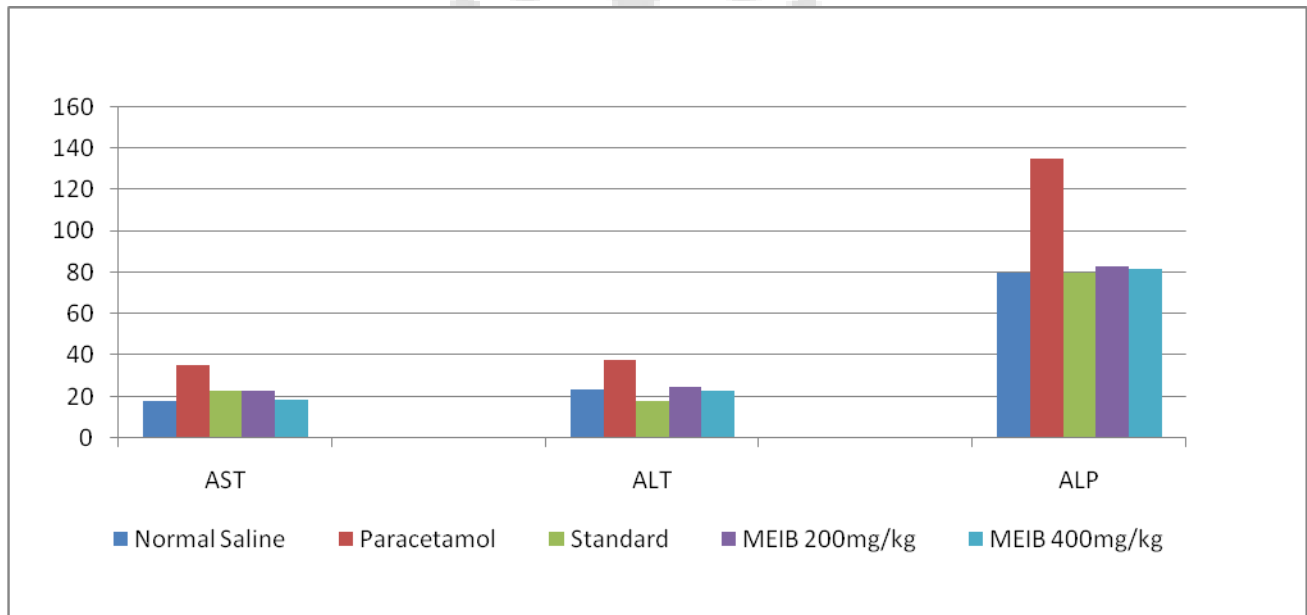
The level of reduced glutathione (GSH and SOD) was significantly ( $p < 0.01$ ) depleted in paracetamol control group as compared with normal control group. Reduced GSH and SOD level were found to be significantly ( $p < 0.001$ ) elevated towards normal level on administration of the extracts as compared with paracetamol control group. There was significant ( $p < 0.001$ ) reduction in catalyses activity in paracetamol control group compared with normal group. Administration of the test extract significantly ( $p < 0.001$ ) recovered the CAT activity towards normal when compared with paracetamol controlled animals acylation (Table 4).

**Body Weight, Liver and Kidney Weights:** The body weight and liver weights of rats from paracetamol control group (after 7 days) were significantly ( $p < 0.001$ ) decreased when

compared with normal control group. The extract at 400mg/kg b.w. significantly ( $p < 0.001$ ) maintained the body weight and liver weights towards normal as compared to paracetamol control (Table 5).

**Table: 2 Effect of *Indigofera barberi* on serum AST, ALT and ALP levels in paracetamol induced acute liver injury in rats**

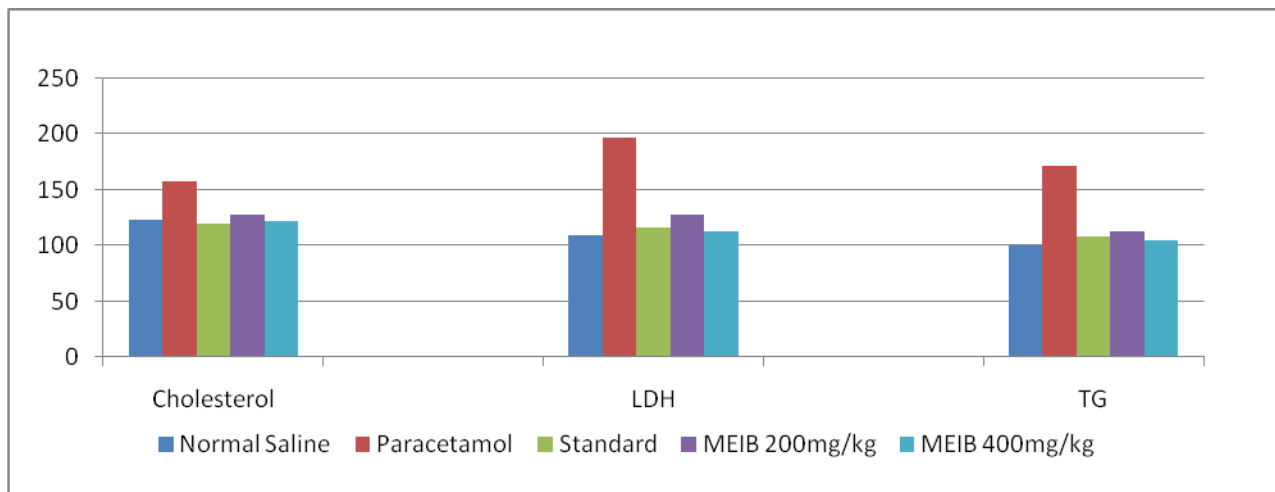
Groups	AST	ALT	ALP
Normal Saline	18 ± 1.78	23.33 ± 2.4	79.83 ± 4.49
Paracetamol	35.5 ± 2.88	37.5 ± 4.8	134.83 ± 4.57
Standard	23 ± 2.8***	17.83 ± 2.316***	80 ± 3.74***
MEIB 200mg/kg	22.83 ± 2.99***	24.83 ± 2.85***	82.83 ± 4.66***
MEIB 400mg/kg	18.8 ± 1.94***	23.16 ± 3.8***	81.66 ± 5.16***



**Fig.2: Effect of *Indigofera barberi* on serum AST, ALT and ALP levels in paracetamol induced acute liver injury in rats**

**Table: 3 Effect of *Indigofera barberi* serum biochemical levels in paracetamol induced acute liver injury in rats**

Groups	Cholesterol	Ldh	Tg
Normal Saline	123.16 ± 2.56	109.5±4.278	100.33 ± 4.17
Paracetamol	157.66 ± 3.32	197.5±3.082	172 ± 4.8
Standard	120 ± 2.60***	115.833±4.49***	108.3 ± 4.17***
MEIB 200mg/kg	127.66 ± 3.2***	128.3±2.8	113.16 ± 2.9***
MEIB 400mg/kg	121.66 ± 3.3***	112.6±5.8***	105.33 ± 2.06***

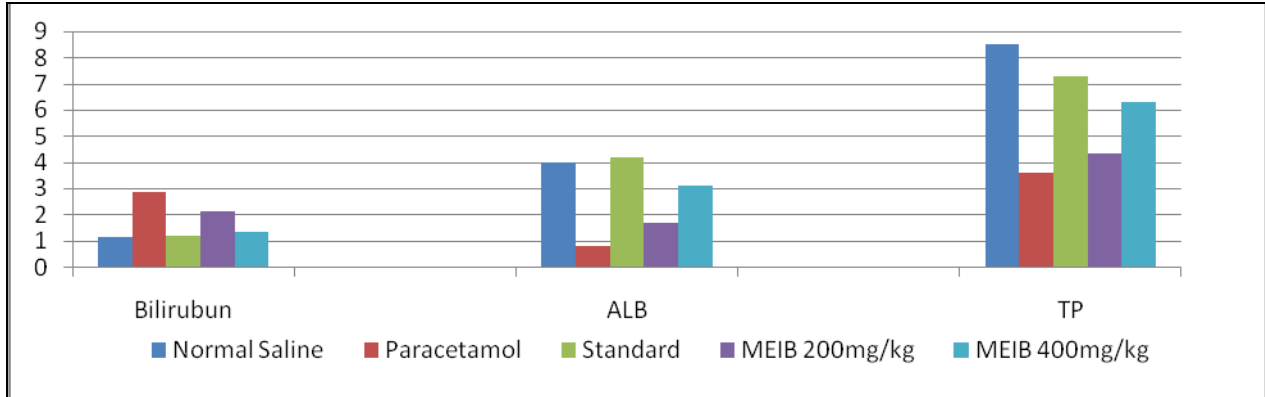


**Fig.3: Effect of *Indigofera barberi* serum biochemical levels in paracetamol induced acute liver injury in rats**

**Table: 4 Effect of *Indigofera barberi* on serum bilirubin, albumin and total protein levels in paracetamol induced acute liver injury in rats**

Groups	Bilirubin	Albumin	Total Protein
Normal Saline	1.11 ± 0.26	4±1.788	8.5 ± 2.6
Paracetamol	2.83 ± 1.47	0.766±0.1751	3.57 ± 1.04
Standard	1.16 ± 0.40**	4.166±1.602***	7.3 ± 1.8
MEIB 200mg/kg	2.1 ± 1.60**	1.66±0.77**	4.33 ± 1.03**
MEIB 400mg/kg	1.33 ± 0.51**	3.12±2.3***	6.3 ± 2.3***

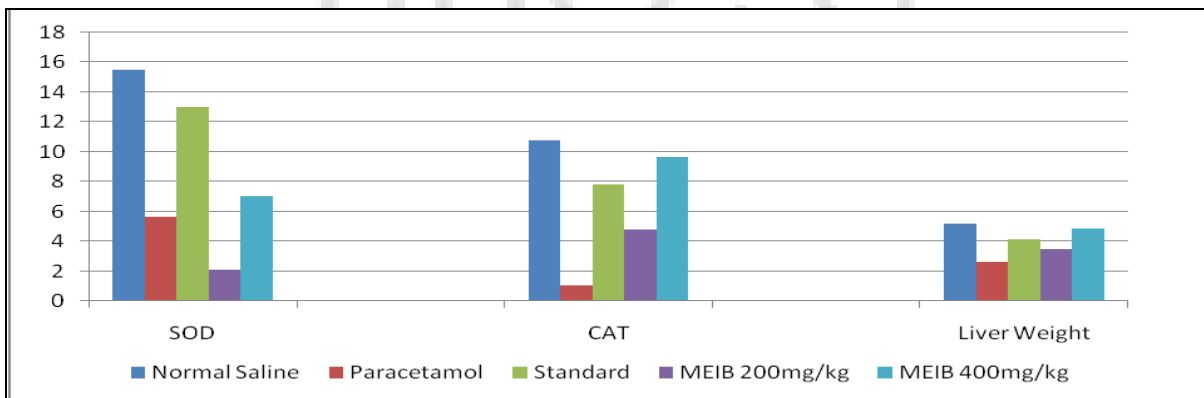




**Fig.4: Effect of *Indigofera barberi* on serum bilirubin, albumin and total protein levels in paracetamol induced acute liver injury in rats**

**Table 5: Effect of *Indigofera barberi* on serum SOD, CAT and liver weight on paracetamol induced acute liver injury in rats**

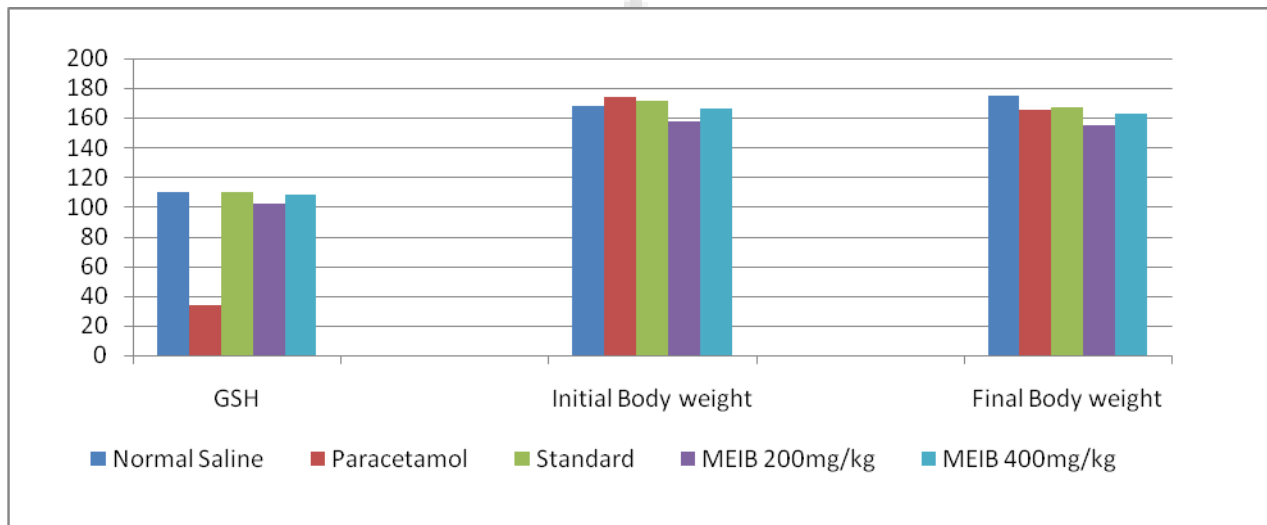
Groups	SOD	CAT	Liver Weight
Normal Saline	15.5±3.619	10.8 ± 2.8	5.16 ± 2.6
Paracetamol	5.667±3.55	1.04 ± 0.47	2.66 ± 1.63
Standard	13.0±4.050***	7.8 ± 2.7***	4.16 ± 1.47***
MEIB 200mg/kg	2.1±0.75**	4.8 ± 2.3***	3.5 ± 1.87***
MEIB 400mg/kg	7.00±2.608***	9.66 ± 2.1***	4.83 ± 1.47***



**Fig.5: Effect of *Indigofera barberi* on serum SOD, CAT and liver weight on paracetamol induced acute liver injury in rats**

**Table 6: Effect of *Indigofera barberi*, *Rhyncosia beddomei* and *Trichuriella monsoniae* on serum GSH and body weight on paracetamol induced acute liver injury in rats**

Groups	GSH	Initial Body Weight	Final Body Weight
Normal Saline	110.33 ± 6.02	168.3 ± 5.12	174.83 ± 2.63
Paracetamol	33.3 ± 3.8	173.8 ± 3.4	165 ± 3.74
Standard	109.83 ± 4.3***	171.8 ± 3.4***	167.16 ± 4.9***
MEIB 200mg/kg	102.5 ± 4.96***	158 ± 5.2***	155.16 ± 4.4***
MEIB 400mg/kg	108.5 ± 4.80***	165.83 ± 3.4***	162.66 ± 3.72***



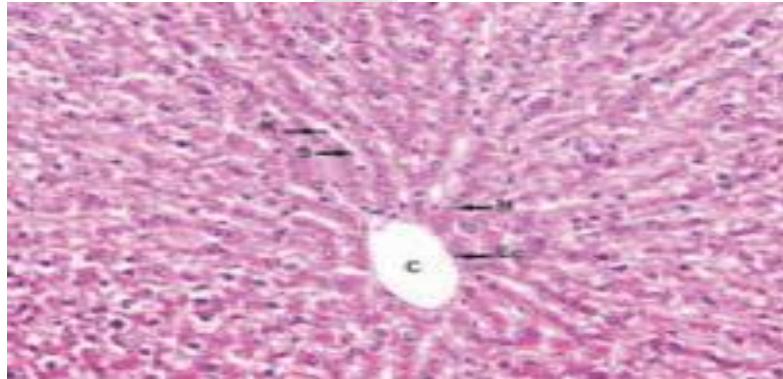
**Fig.6: Effect of *Indigofera barberi*, *Rhyncosia beddomei* and *Trichuriella monsoniae* on serum GSH and body weight on paracetamol induced acute liver injury in rats**

### Histopathology

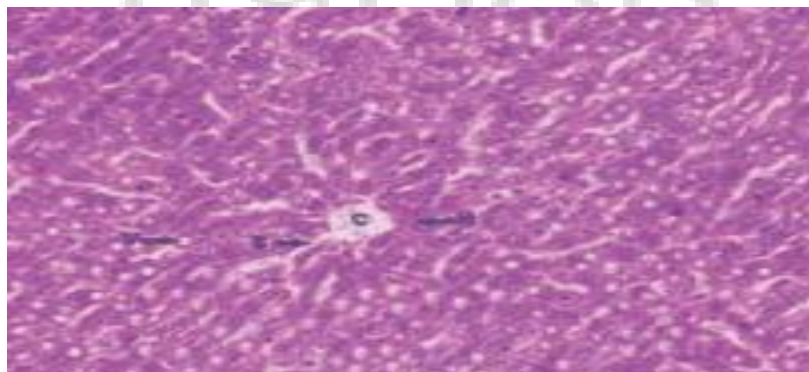
The histopathological study showed recovery of the damaged liver cells in the drug treated group. The reputed cells of the intoxicated liver were reformed. The degree of vascularization was also reduced as compared to hepatotoxic group. Multiple foci of inflammation and necrosis noticed in centrilobular region of liver. Also, infiltration of inflammatory cells noticed in the inflammatory region of liver. (a) Control group (received distilled water for 10 days) showing normal architecture of hepatic cells. (b) Paracetamol (500mg/kg) treated group showing

centrilobular degeneration, necrosis of hepatic cells. (c) Paracetamol (500mg/kg for the last 7 days) + MEIB 400mg/kg showing complete regeneration and almost normal architecture of hepatocytes. (e) Paracetamol (500mg/kg) + Silymarin 25mg/kg showing complete regeneration and normal architecture of hepatocytes.

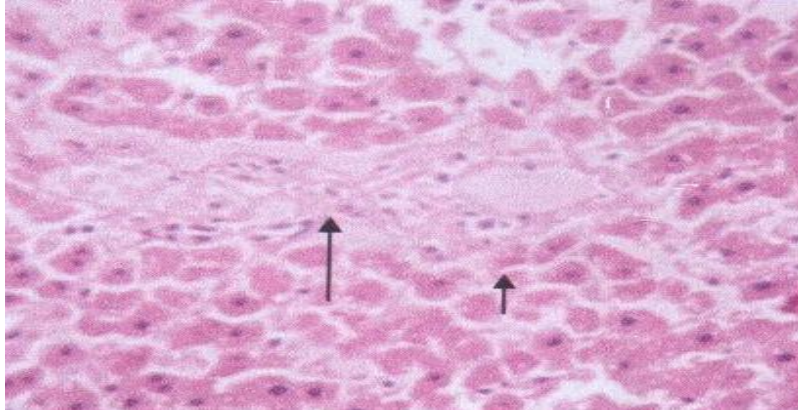
In normal rat liver bile duct appeared normal, portal triad appeared normal & no inflammation or fibrosis noticed surrounding the portal region of liver. In Paracetamol control rat there is mild to moderate bile duct hyperplasia or bile duct proliferation noticed surrounding the portal region of liver. In Methanolic extract of *Indigofera barberi* Gamble (400mg/kg) treated rat liver small foci of periportal inflammation with infiltration of inflammatory cells noticed in the liver. In standard silymarin (25mg/kg) rat liver hepatocytes appeared normal, periportal and centrilobular region appeared normal but mild sinusoidal space dilatation noticed in the periportal region of liver.



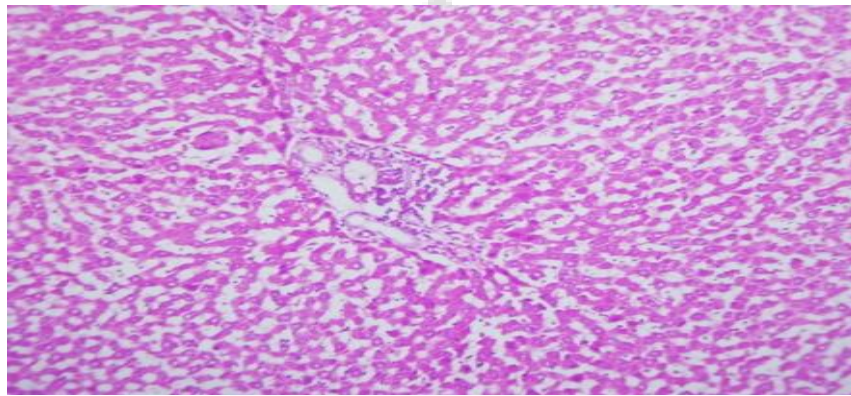
**Fig. 7.** Control group. The liver tissue of mice belonging to control group showing normal histological architecture, with central vein (CV) from which chords of hepatocytes are radiating. H& E stain 100 X. PV, portal vein; BD, bile duct.



**Fig. 8.** Paracetamol induced hepatotoxicity. (A): Paracetamol induced hepatotoxicity showing extensive areas of confluent necrosis and also showing fatty changes and hydropic degeneration. H& E stain 100X.



**Fig. 9.** Pre-treatment with standard; showing complete protection of hepatocytes showing complete normalization of liver architecture. H & E stain 40 and 100 X.



**Fig. 10.** Pre-treatment with *Indigofera barberi* showing complete protection of hepatocytes showing complete normalization of liver architecture. H & E stain 40 and 100 X.

## DISCUSSION

Preliminary phytochemical investigation of methanol extract was found to contain carbohydrates, flavonoids, phenolic compounds and tannins. Alkaloids, flavonoids and saponins are known to possess hepatoprotective activity. Acute toxicity studies of methanolic extract at the dose of 4000mg/kg showed no toxic symptoms or death in any of the animals up to one week and till the end of the study. Thus the drug was considered to be safe.

Liver injury caused by paracetamol is due to its metabolite which leads to the hepatic oxidative damage generating immune-allergic reactions. Severe inflammatory changes with collagenous septa beginning to form after pronounced centrilobular and bridging necrosis. In the parenchyma,

there was focal liver cell necrosis with some accumulation of histolytic elements and slight steatosis and cholestasis. Portal tract shows fibrosis, bile duct proliferation and infiltrate consisting of lymphocytes plasma cells, polymorphs and eosinophils.

Liver injury is manifested in terms of increase in levels of serum aminotransferases, modest hepatic infiltration by both lymphocytes and eosinophil's and slight focal hepatocellular necrosis also causes liver cholestasis associated with increased plasma bilirubin and alkaline phosphatase<sup>11</sup>. Paracetamol (acetaminophen) is a commonly and widely used analgesic and antipyretic agent. Hepatotoxic doses of acetaminophen deplete the normal levels of hepatic glutathione when NAPQI covalently binds to cysteine groups on proteins to form 3-(cysteinS-yl) acetaminophen adducts. The glutathione protects hepatocytes by combining with the reactive metabolite of paracetamol thus preventing their covalent binding to liver proteins<sup>12</sup>. Aminotransferases ALT and AST catalyze the interconversion of amino acids and  $\alpha$ -keto acids by the transfer of an amino group. These enzymes are very sensitive and are reliable indices for hepatoprotective or curative effects of various compounds. Elevated levels of ALT, AST, ALP and bilirubin were observed in positive control group and were reduced significantly in all drug treated groups.

Liver cells synthesize various proteins like albumin, fibrinogen, hepato globin, transferrin and antitrypsin. The blood levels of these proteins are decreased in extensive liver damage. Serum proteins levels were found to decrease in positive control group which was reversed in extract treated group. Serum enzyme levels are not a direct measure of hepatic injury, but elevated levels are indicative of cellular leakage and loss of integrity of cell membrane. Thus lowering of enzyme content in serum is a definite indication of hepatoprotection of the drug. The marker enzyme levels in different group of animals are measured. The serum levels of ALT, AST and ALP were increased significantly. In our study, the administration of methanolic extract 400mg/kg, p.o showed significantly reduced levels of ALT, AST and ALP whereas the total protein levels were increased significantly in the extract treated group. The results clearly indicated that extracts were capable of lowering the serum levels of ALT, AST and ALP.

Table 2 represents the changes in the levels of bilirubin, cholesterol TG and LDH activity. Table 3 represents the changes in the enzymatic of AST, ALT, ALP and the levels of TP and serum

Albumin. Table 4 represents the changes in the liver biochemical parameters (enzymatic activities) of SOD, GSH and CAT.

Elevated levels of serum enzymes are indicative of cellular leakage and loss of functional integrity of cell membrane in liver<sup>13</sup>. Hepatocellular necrosis leads to high level of serum markers in the blood, among these, aspartate transaminase, alanine transaminases represents 90% of total enzyme and high level of alanine transaminase in the blood is better to index of liver injury, but the elevated levels of enzymes are decreased to near normal levels after seven days treatment of *Indigofera barberi* Gamble indicates that it offered protection by preserving the structural integrity of the hepatocellular membrane against paracetamol. Alkaline phosphatase concentration is related to the functioning of hepatocytes, high level of alkaline phosphatase in the blood serum is related to the increased synthesis of it by cells lining bile canaliculi usually in response to cholestasis and increased biliary pressure<sup>14</sup>. Increased level was obtained after paracetamol administration and it was brought to near normal level by *Indigofera barberi* Gamble treatment. Lactate dehydrogenase is localized in the cytoplasm of cells and thus is extruded into the serum when cells are damaged or necrotic. The measurement of total lactate dehydrogenase can be useful when only a specific organ, such as the liver, is known to be involved. Lactate dehydrogenase is increased in acute necrosis of the liver. Lactate dehydrogenase is a sensitive intracellular enzyme which increases in serum is also an indication of liver cell damage<sup>15</sup>. Treatment with *Indigofera barberi* Gamble at a dose of 400mg/kg significantly reduced the elevated levels of those enzymes.

The above changes can be considered as an expression of the functional improvement of hepatocytes, which may be caused by an accelerated regeneration of parenchymal cells. Protein metabolism is a major project of liver and a healthy functioning liver is required for the synthesis of the serum proteins except for the  $\gamma$  globulins. Hypoproteinemia is a feature of liver damage due to significant fall in protein synthesis. Albumin is decreased in chronic liver disease and is generally accompanied by an increase in the  $\beta$  and  $\gamma$  globulins as a result of production of IgG and IgM<sup>16</sup>. Hypoproteinemia was observed after paracetamol ingestion but the trend turns towards normal after *Indigofera barberi* Gamble treatment. Serum bilirubin is one of the most sensitive tests employed in the diagnosis of hepatic diseases. Hyperbilirubinemia was observed due to excessive heme destruction and blockage of biliary tract. As a result of blockage of the

biliary tract there is a mass inhibition of the conjugation reaction and release of unconjugated bilirubin from damaged and dead hepatocytes<sup>17</sup>. Administration of *Indigofera barberi* Gamble decreased the level of bilirubin and increased the level of protein suggesting that it offered protection. Paracetamol seems to cause impairment in lipoprotein metabolism<sup>18</sup> and also alterations in cholesterol metabolism. The levels of cholesterol and triglyceride were significantly increased in paracetamol treated rats, when compared to control, silymarin and *Indigofera barberi* Gamble treated rats. Elevation of triglycerides level during paracetamol intoxication could be due to increased availability of free fatty acids, decreased hepatic release of lipoprotein and increased esterification of free fatty acids. Administration of *Indigofera barberi* Gamble significantly decreased serum lipid profile in paracetamol toxicity induced rats because of its hypolipidemic effects.

Histopathology studies of liver photomicrographs of different groups were shown normal liver control showed normal hepatic architecture with portal tracts, central veins, hepatocytes and sinusoids. The section of the liver of the toxic control group of animals exhibited severe intense congestion, hydropic degeneration, pyknosis and occasional necrosis. Positive control group showed loss of normal liver architecture with degenerative hepatocytes, fibrosis, sinusoidal spaces with inflammatory cells, ballooning of cells and centrilobular necrosis and with few fatty globules. Liver photomicrograph of drug extract (400mg/kg) showed mild fibrosis, light hepatocyte regeneration and ballooning of hepatocytes, Treatment with standard silymarin (25 mg/kg) showed almost normal liver architecture.

## CONCLUSION

The results of the present study clearly demonstrate the hepatoprotective property of methanolic extract of *Indigofera barberi* Gamble with histopathological evidence. The phytochemical study revealed the presence of flavonoids, tannins phenols etc. The flavonoids showed the protective effect of liver in liver injury caused by paracetamol in rats. The above compounds may contribute to presence of hepatoprotective activity. Further studies are required to isolate, characterize and find out the mechanism of action of active compounds in methanolic extract of *Indigofera barberi* Gamble that is responsible for hepatoprotective activity.

## REFERENCES

1. Patel RK, Patel MM, Kanzaria NR, Vaghela NR, Patel NJ, Liver functions magazine, 4, 2008, 118-119.
2. DeFeuids FV, Papadopoulos V, Drieu K, "Ginkgo biloba extracts and cancer: a research area in its infancy", *Fundam Clin Pharmacol*, 17, 2003, 405-417.
3. Banskota AH, Tezuka Y, Adnyana IK, Xiong Q, "Herbal plants as natural remedies", *Biol Pharm Bull*, 23, 2000, 456-460.
4. Mossa JS, Tariq M, Mohsin A, Aqeel AM, AlYahya MA, "Pharmacological studies on aerial parts of *Calotropis procera*", *Am. J. Clin. Med.*, 19, 1991, 223-231.
5. Mascolo N, Sharma R, Jain SC, Capasso F, "Ethnopharmacology of *Calotropis Procera* Flowers", *J. Ethnopharmacol*, 22, 1998, 211- 216.
6. Dash DK, Yeligar VC, Nayak SS, Ghosh T, Rajalingam D, Maiti BC, Maity TK, "Evaluation of hepatoprotective and antioxidant activity of *Ichnocarpus frutescens* (Linn) on Paracetamol induced hepatotoxicity in rats", *Trop. J. Pharm. Res.*, 6, 2007, 755-765.
7. Rajeshwar T, Rao KNV, Sandhya S, David Banji, Murali Krishna P, Sunitha Ch, "Pharmacognostical standardization of leaf extract of *Indigofera barberi* (Fabaceae)," *Scholars Research library*, 1(4), 2011, 60-65.
8. Palani S, Senthil Kumar B, Praveen Kumar R, Devi K, Venkatesam D, Raja Sathendra, "Effect of ethanolic extract of *Indigofera barberi* in acute acetaminophen induced nephrotoxic rats", *Advanced Biotech*, 7(3), 2008, 28-31.
9. Tadigoppula N, Tanvir K, Anju P, Ramesh C, "Antidyslipidemic activity of furanoflavonoids isolated from *Indigofera tinctoria*", *Bioorganic Med. Chem. Letters* 16, 2006, 3411-3414.
10. N. Kanchana and A. Mohamed Sadiq "Hepatoprotective effect of *Plumbago zeylanica* on paracetamol induced liver toxicity in rats" *Inter.J. of Pharma and Phar Sci.* 2011, 3(1), 152-154.
11. Kind PR, King EJ, "Estimation of Plasma phosphates by determination of hydrolyzed Phenol with Antipyrine", *J. Clin. Pathol.* 7: 1954, 322-330.
12. Drotman RB, Lawhorn GT. "Serum enzymes are indicators of chemical induced liver damage". *Drum Chem Toxicol* 1978; 1: 163-71.
13. Gaw A, Cowan RA, O'Reilly DSJ, Stewart, MJ Shepherd J. *Clinical biochemistry – an illustrated color text.* 1st ed. New York: Churchill Livingstone; 1999. p. 51-3.
14. Kim KA, Lee WK, Kim JK, Seo MS, Lim D, Lee KH " Mechanism of refractory ceramic fibre- and rock wool-induced cytotoxicity in alveolar macrophages". *Arch Occup Environ Health*, 2001; 74:9-15.
15. Kaplan LA, Pesce AJ. *Clinical chemistry.* 3rd ed. St. Louis, MO: Mosby; 1996. p. 517.
16. Wolf A, Diez-Fernandez C, Trendelenburg CF, Prieto P, Hary S, Trammer WE. Paracetamol induced oxidative stress in rat hepatocytes. *J Pharm Exp Ther* 1997; 280:1328-34.
17. Kobashigania JA, Kasiska BL. Hyperlipidemia in solid organ transplantation. *Transplantation* 1997; 63:333-8.