



IJPPR

INTERNATIONAL JOURNAL OF PHARMACY & PHARMACEUTICAL RESEARCH  
An official Publication of Human Journals

ISSN 2349-7203





Human Journals

**Case Report**

December 2019 Vol.:17, Issue:1

© All rights are reserved by G. Ramya Kumari et al.

## Case Report on Snake Bite Induced Local and Systemic Effects (Cellulitis, AKI & ARDS)

	
<p><b>K Thirumala Naik<sup>1</sup>, B. Aiswarya<sup>2</sup>, G. Ramya Kumari<sup>*3</sup></b></p> <p>1. <i>Asst. Professor, Department of Pharmacy Practice, SVIMS Hospital, Krishna Teja Pharmacy College, Tirupati.</i></p> <p>2. <i>Pharm.D Intern, SVIMS Hospital &amp; Krishna Teja Pharmacy College, Tirupati.</i></p> <p>3. <i>Pharm.D Intern, SVIMS Hospital &amp; Krishna Teja Pharmacy College, Tirupati.</i></p> <p><b>Submission:</b> 25 November 2019 <b>Accepted:</b> 30 November 2019 <b>Published:</b> 30 December 2019</p>	

**Keywords:** Acute Kidney Injury, Acute Respiratory Distress Syndrome, Shortness of Breath, Anti Snake Venom

### ABSTRACT

Snake bites present as life-threatening emergencies and is seen more commonly in rural tropical countries. Snakebites have Neurotoxic, Hemotoxic, Myotoxic or mixed presentation. We present a case of 55 years old male patient from Rural Area who presented with a history of having been bitten by a snake (Russell's viper). Without any first aid, the patient went to local hospital after 40 minutes where he was treated with 3 vials of anti-venom and this inappropriate dose and delay in administration of anti-venom, the patient developed systemic (AKI and ARDS) and local effects (CELLULITIS) and then he was referred to tertiary care hospital and further management was given to the patient and his condition was improved at the time of discharge. Hence first aid, prompt diagnosis and timely administration of anti-venom are mandatory for venomous snake bite.



HUMAN JOURNALS

[www.ijppr.humanjournals.com](http://www.ijppr.humanjournals.com)

## INTRODUCTION

Snakebite is a common medical emergency but the exact estimates of consequent morbidity and mortality are not known due to lack of adequate reporting.<sup>1</sup> Venomous snakebite was listed as an NTD-"Neglected Tropical Disease", by the WHO in 2009, that mainly affects poor farming communities in the rural tropics.<sup>2,3</sup>

In India, more than 2,000,000 snakebites are reported annually, of which 35,000–50,000 people die. Russell's viper is the leading cause of fatal snake bite in India.<sup>4</sup>

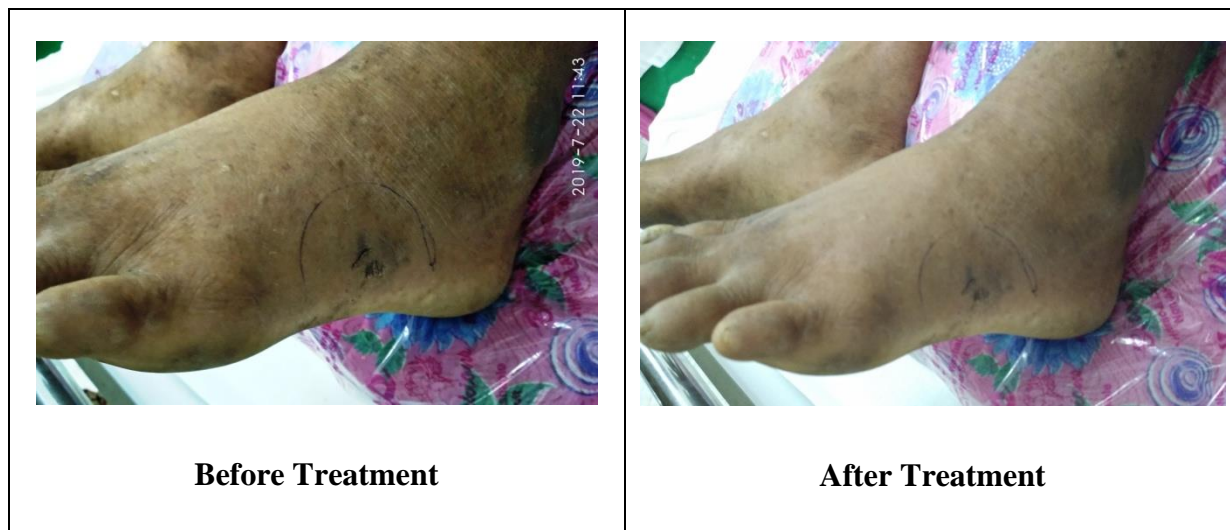Snake venom is a mixture of various enzymes, nonenzymatic polypeptides, and non-toxic proteins.<sup>1</sup> Snake envenomation can cause acute local and systemic effects due to the actions of toxic components in the venom.<sup>2</sup> Proteolytic enzymes are responsible for local changes in permeability leading to edema, blistering, bruising and local necrosis.<sup>5</sup> The commonest important systemic manifestations of snake envenoming are venom-induced consumption coagulopathy, neuromuscular paralysis, acute kidney injury, myotoxicity, and cardiovascular collapse.<sup>2,6&7</sup> Some elapid and Viperidae snakes cause tissue injury at the bite site, manifesting initially with edema, pain, redness and blistering. In more severe cases, there may be subsequent dermonecrosis and myonecrosis, occasionally requiring debridement and rarely amputation.<sup>2, 6, 7</sup>

Antivenom (antivenin) is a biological product used in the treatment of venomous bites or stings.<sup>8</sup> Polyvalent Antivenom available in India acts against krait, cobra, Russell's viper, and Echis. It accelerates the dissociation of the toxin receptors complexes and reverses the paralysis. Anti snake venom (ASV) neutralizes circulating venom and it has no action once the venom is attached to the receptor site. Antivenom should be administered as soon as signs of systemic or severe local swelling are noted.<sup>5</sup>

## CASE REPORT

A 55-years old male patient from rural area was admitted in the Department of Emergency Medicine, SVIMS Hospital, Tirupati on 21<sup>st</sup> July 2019 with the chief complaints of left lower limb edema, SOB (Shortness of Breath) sudden onset gradually progressive (Grade-IV) ARDS (SPO2: 86%:RR: 32 CPM) and 6 episodes of vomitings with haematemesis and was alleged case of Snake Bite(Russell's viper) at lateral aspect of left lower limb on 20<sup>th</sup> July 2019 at 8 am while walking in his field on agriculture works, on that day he was taken 3

Vials of Anti snake venom (ASV) at local Hospital, after 40 minutes of snakebite without any First Aid and after going home from the local hospital at night he experienced 6 episodes of vomitings. He was a known case of CAD (Coronary Artery Disease) for 13 years, the physician advised angiogram but he didn't yet, now he was on regular medication.



**Figure No: 1: localization of Snake bite of patient before and after treatment**

On day 1 the patient had c/o SOB, decreased urinary output, facial puffiness, and swelling of left lower limb and elevated parameters are Sr.Urea (146 mg/dl), Sr.Creatinine (5mg/dl), SGOT (152 IU/L), LDH (27382IU/L) decreased platelet count (37000/cumm) for which he was treated with following medications Inj.ASV 10 vials in 1-pint normal saline over 4 hours, Inj.AVIL 2cc, Inj Hydrocortisone 100mg, Inj. PIPTAZ 2.25gms in 100 ml normal saline, Inj. METROGYL 500 mg, Inj PAN 40mg, Inj.vitamin K 10mg, IVF 2 pint DNS & NS, left lower limb MgSO<sub>4</sub> dressing with lower limb elevation.

On day-2 the patient had complaints of pain at the left lower limb (At the site of snake bite) since morning and elevated parameters include Sr.Urea (167mg/dl), Sr.Cr (5.8mg/dl), and SGOT (187IU/L). He was treated with the same medication as of day 1 along with added Inj. LASIX -40mg in the morning and during the night time on examination patient had Left leg cellulitis and was treated with Inj. XTUM-1.5gms, Inj. Clindamycin 600mg, Tab.NODOSIS, Cap. NEFITA, Tab. CHYMORAL FORTE, Inj. RANTAC 50mg, Inj. ZOFE-4gms SOS in the night. On day- 3 he was treated with the same medication as of day 2 except Inj.ASV, Inj. AVIL, Inj Hydrocortisone, Inj. PIPTAZ, Inj. METROGYL, Inj PAN, and Inj. Vitamin K.

On days 4-7 the patient had the same complaints and decreased Haptoglobin (<10mg/dl) and elevated Prothrombin time (30sec). On the eighth day, the patient had C/O swelling of both lower limbs and was treated with the medication and the patient underwent 14 times dialysis (12-hemodialysis, 2-plasma perfusion in 38 days) on alternative days until the patient condition is improved and on 38<sup>th</sup>-day patient was recovered with improved urine output (3.5 liters/day), became nondialysis dependant, Sr. Creatinine was decreased (2.19mg/dl) and was discharged with the following medications Tab.NODOSIS, Tab.RANTAC, Cap.NEFITA.

**First, follow up** – when a patient came for followup after 10 days the Sr.Creatinine levels were found to be 1.9mg/dl.

**Second Follow up** – Creatinine levels were found to be normal (1.4 mg/dl).

### LABORATORY EXAMINATIONS

**Table no: 1 Laboratory Abnormalities**

Day -1		Day -2			
Parameters	Observed values	CBP:	Observed values	LFT:	Observed values
Hb	13.8 g/dl	Hb	13.7 %	T.B	1.8
RBC	4.12 ×10 <sup>12</sup> /L	RBC	4.44	C.B	0.4
Total WBC	19/300 c/cumm	PT	37000	SGOT	152
Neutrophils	78 %	B.T	3.3mins.	SGPT	21
Lymphocytes	14	C.T	6.3mins.	Albumin	2+
Platelet Count	0.33 ×10 <sup>9</sup> /L	PTT	16.6 sec		
MCH	33.2 pg	INR	1.47		
ESR	40 mm/hr	<b>RFT</b>		<b>Electrolytes</b>	
		Sr. Cr	5.0	Na+	141
		S. Urea	146	K+	5.3

*Note: P.T: Platelet Count; T.B: Total Bilirubin; C.B: Conjugated Bilirubin.*

### DISCUSSION

Snakebites have the highest incidence in Asia and represent an important health problem. The majority of snake bites occurred between 6 AM to 10 PM i.e., during working hours in the

field. As expected the snake bites more commonly involves in lower limbs.<sup>9</sup> acute kidney injury (AKI) is an important complication of snakebite and a major cause of mortality. AKI is common after bites from myotoxic or hemotoxic snakes.<sup>10</sup>

In our case, the patient alleged with snakebite at the lower limb while working in his field. Snakebite induces both topical and systemic effects. In our case study the patient experienced both topical (cellulitis) and systemic effects (AKI and ARDS).

Topical Effects (Cellulitis): After a snake bite, the patient developed pain and swelling due to cellulitis. Systemic Effects (AKI & ARDS): Acute respiratory distress syndrome (hypoxia, SOB Grade-IV), Renal failure, hematemesis, and oliguria.

The patient in our case directly went to the hospital without any first aid after 3 hrs of snake bite. In general, the first aid for snakebite includes verbal support, immobilization, tourniquet, and cryotherapy and incision therapy at the site of the bite. After undergoing any of the above procedures the patient must go immediately to the hospital because there might be a chance of bleeding or necrosis.

The only effective antidote for snake venom is anti-snake venom. Along with the anti-snake venom symptomatic treatment should be provided to the patient. Delay in administering anti-venom and inappropriate doses are common among the patients who developed AKI.<sup>11</sup>

In our case, initially, the patient was given 3 vials of ASV, this inappropriate dose leads to systemic toxicity. Due to this, the patient was again admitted to the hospital for further management, where he was treated with 10 vials of ASV in 1 pint NS over 4 hrs along with supportive therapy. The patient was kept under 48hrs observation in which the patient vitals, CBC, Creatinine, BUN, Urine output, ECG were monitored. Gradually the patient condition was improved (increased urine output, decreased serum Creatinine levels, decreased swelling) and hence biopsy was not preferred.




## CONCLUSION

Snakebite is a significant health problem in India, particularly in the rural regions of the country. In general, about 70% of bites are nonpoisonous of the rest 15% are dry bites and only 15% cause envenomation.

We conclude that first aid is mandatory for any snakebite as it decreases the systemic absorption of venom, thereby reduces further complications. Prompt diagnosis and timely administration of Anti Snake Venom can not only be life-saving but also prevent mortality rate. Preventive measures like wearing high top leather boots while walking through or working in areas of dense vegetation may reduce the incidence of snakebite.

## REFERENCES:

1. Jaideep C Menon, Joseph K Joseph, Romulus E Whitaker, Venomous Snake Bite in India - Why do 50,000 Indians Die Every Year, Journal of The Association of Physicians of India, August 2017, Vol. 65, 78-81.
2. Durgadas Anghore, Amit Sharma<sup>1</sup>, Shamsheer Singh<sup>1</sup>, Sourabh Kosey<sup>1</sup>, Shammy Jindal Treatment of Snake Bite in India: A Review International Journal of Pharmacy Teaching & Practices 2015, Vol.6, Issue 4, 2635-2641.  
<https://www.researchgate.net/publication/325988432>.
3. Isbister, G.K. Snakebite doesn't cause disseminated intravascular coagulation: coagulopathy and thrombotic microangiopathy in snake envenoming Semin. Thromb. Hemost. **2010**, 36, 444–451.  
<https://www.thieme-connect.de/products/ejournals/abstract/10.1055/s-0030-1254053>.
4. VK Pothukuchi, VR Chepuri, Kalyani Natta, Nagaraju Madigani and Alok Kumar, A rare case report of Russell's viper snakebite with ischemic stroke, Hong Kong Journal of Emergency Medicine 2018, Vol. 25(2) 95–97.
5. J.P. Kachhawa, Ankita Sharma, Tanuj K. Tanwar and A.P. Singh, Therapeutic management of snakebite in buffalo- A Case Report, Indian J. Vet. Med. Vol. 36, No. 2, 2016. 134-135.
6. Isbister, G.K. Snakebite doesn't cause disseminated intravascular coagulation: coagulopathy and thrombotic microangiopathy in snake envenoming. Semin. Thromb. Hemost. 2010, 36, 444–451.
7. Sitprija, V. Snakebite nephropathy. Nephrology 2006, 11, 442–448. 7.  
<https://www.ncbi.nlm.nih.gov/pubmed/17014559>
8. Durgadas Anghore, Amit Sharma<sup>1</sup>, Shamsheer Singh<sup>1</sup>, Sourabh Kosey<sup>1</sup>, Shammy Jindal Treatment of Snake Bite in India: A Review International Journal of Pharmacy Teaching & Practices 2015, Vol.6, Issue 4, 2635-2641. <https://www.researchgate.net/publication/325988432>
9. Tushar B Patil, Yogendra V Bansod. Snake bite-induced acute renal failure: A study of clinical profile and predictors of poor outcome, Annals of Tropical Medicine and Public Health, 2012, Vol 5, Issu 4, 335-339.  
<http://www.atmph.org/article.asp?issn=1755-6783;year=2012;volume=5;issue=4;spage=335;epage=339;aulast=Patil>
10. Sanjay Vikrant, Ajay Jaryal, Anupam Parashar. Clinicopathological spectrum of snake bite-induced acute kidney injury from India World J Nephrol 2017 May 6; 6(3): 150-161.
11. VV Pillay, Modern Medical Toxicology, 4<sup>th</sup> Edition, Jaypee brothers, 2013, 150-156.

	<p><b>Dr. K THIRUMALA NAIK</b> <i>Clinical Pharmacist &amp; Asst. Professor</i> <i>Krishna Teja Pharmacy College &amp; SVIMS Hospital,</i> <i>Tirupati.</i></p>
	<p><b>B AISWARYA</b> <i>Pharm.D internship</i> <i>Krishna Teja Pharmacy College &amp; SVIMS Hospital,</i> <i>Tirupati.</i></p>
	<p><b>G RAMYA KUMARI</b> <i>Pharm.D internship</i> <i>Krishna Teja Pharmacy College &amp; SVIMS Hospital,</i> <i>Tirupati.</i></p>

