



IJPPR

INTERNATIONAL JOURNAL OF PHARMACY & PHARMACEUTICAL RESEARCH
An official Publication of Human Journals

ISSN 2349-7203




Human Journals

Case Report


March 2020 Vol.:17, Issue:4

© All rights are reserved by Nandyala. Bhargavi et al.

Congenital Myasthenia Syndrome: A Case Report



IJPPR
INTERNATIONAL JOURNAL OF PHARMACY & PHARMACEUTICAL RESEARCH
An official Publication of Human Journals



ISSN 2349-7203

Nandyala. Bhargavi*¹, Yeruva. Veena², Bandaru. Jeevani³

^{1,2,3}Pharm D students Interns, Nirmala college of pharmacy, Guntur, 522503, Andhra Pradesh

Submission: 22 February 2020
Accepted: 29 February 2020
Published: 30 March 2020

Keywords: congenital myasthenia syndrome, acetylcholine, muscle weakness

ABSTRACT

The Congenital Myasthenia Syndromes (CMS) are a diverse group of disorders that have an underlying defect in the transmission of signals from nerve cells to muscles. These disorders are characterized by muscle weakness, which is worsened upon exertion. The age of onset, severity of presenting symptoms and distribution of muscle weakness can vary from one patient to another. The neurotransmitter, acetylcholine, or ACh for short that acts as a chemical 'messenger' with instructions for the muscles to contract. A three years old child female patient was brought to our department with the complaints of drooping of the left eyelid after one week she developed drooping of right eye. With clinical and laboratory findings, she was diagnosed with congenital myasthenia and treatment was started.



HUMAN JOURNALS

www.ijppr.humanjournals.com

INTRODUCTION

Congenital myasthenia syndromes (CMS) are a heterogeneous group of early-onset genetic neuromuscular transmission disorders due to mutations in proteins involved in the organisation, maintenance, function, or modification of the motor endplate. Myasthenia gravis in infancy and childhood fall into two major groups i.e. acquired autoimmune and congenital¹. CMS are clinically characterised by abnormal fatigability, or transient or permanent weakness of extra-ocular, facial, bulbar, truncal, respiratory, or limb muscles². They can be seen with different etiological factors, including a decrease in vesicles together with insufficient secretion, deficiencies in Ach transferase, and Ach esterase and rapsyn levels in all presynaptic, synaptic, postsynaptic regions³. Greater understanding of the mechanisms of CMS has been obtained from structural and electrophysiological studies of the endplate, and from biochemical studies. Present therapies for the CMS include cholinergic agonists, long-lived open-channel blockers of the acetylcholine receptor ion channel, and adrenergic agonists⁴.

CASE REPORT

A 3yrs female child born out of non-consanguineous marriage in 2011. She was delivered at full term by caesarian section .she achieved all the social, motor, and language milestones at regular intervals without delay. She did not suffer from any major illness and asymptomatic till Jan 2015. In first week of Feb. 2015 she developed drooping of left eyelid, over next 3-4 days noticed to lifting left eyelid with fingers to get clear vision. Nearly one week after similar drooping was observed in right eye. The drooping had worsened over next week to obstruct her vision completely. There was no history of vision loss, facial weakness, facial asymmetry, difficulty in chewing, drooling of saliva, and dysphagia dysarthria or nasal intonation to voice. She had become floppy with neck drop on 2-3 occasions and was not able to sit on her own. These episodes resolved within 15-20 min of giving T.Pyridostigmine there are no family history of similar illness in last three generations. The weight is 11kg and upon investigation cranial nerves –II vision -20/50 at 50cm by allen picture card, able to appreciate light from all corners, VII –bilateral orbicularis oculi-weak and done test for NM junction disorders and also they done investigations such as CBC, electrolytes, MRI brain shows normal, AchR Ab-0.18nmol/l, CECT suggests thymus hyperplasia. She was treated with AchE inhibitors (pyridostigmine) and five days IV methylprednisolone (250mg/day).

DISCUSSION

CMS includes a heterogeneous group of disorders, characterized by dysfunction of NMJ transmission, which are present since birth and are genetically inherited⁵. Although cases of myasthenia gravis during infancy and childhood have been described in the literature since 1960^{6, 7, 8}, the distinction between acquired autoimmune form and congenital forms has been increasingly recognized and emphasized^{9, 10,11,12,13}. This increasing awareness regarding congenital forms of myasthenia gravis was originally described in a paper by Engel and Lambert who succinctly described the nosology of congenital myasthenia syndrome¹⁴. Furthermore, while most cases of acquired autoimmune childhood MG are sporadic, familial aggregates have been observed which may be due to inheritance of HLA haplotypes that predispose to sensitisation of acetylcholine receptor (AChR)⁵. On the other hand, while a positive AChR antibody test excludes the diagnosis of CMS, but a negative test in a sporadic case does not necessarily imply a diagnosis of CMS because a high proportion of juvenile patients with autoimmune MG are also seronegative ¹⁵.

They had done investigations to evaluate CMS

Motor Nerve Studies

2019

N1 : Rt. Facial R1 : Orb. Oculi

Stim Site	Lat I (ms)	Lat II (ms)	Dur (ms)	Amp	Area	Segments	Diff (ms)	Dist (mm)	NCV (m/s)	Curr (mA)
0	SMF	2.48	10.24	7.76	1.09	2.20	2.48	140.00	56.45	25

N1 : Lt. Facial R1 : Orb. Oculi

Stim Site	Lat I (ms)	Lat II (ms)	Dur (ms)	Amp	Area	Segments	Diff (ms)	Dist (mm)	NCV (m/s)	Curr (mA)
0	SMF	2.51	11.47	8.96	1.06	2.76	2.51	140.00	55.78	27

RNS Studies

Rt. Median

Amp	Prex	1 Min	2 Min	3 Min	4 Min	Prex	1 Min	2 Min	3 Min	4 Min
1	2.84	2.69	2.40	1.15	1.56	+0.0	+0.0	+0.0	+0.0	+0.0
2	3.43	3.82	1.80	2.15	1.34	20.77	42.01	-25.00	86.96	14.20
3	3.43	3.50	1.94	1.56	1.32	20.77	30.11	-19.17	35.65	-15.38
4	3.73	3.34	1.92	1.56	1.75	31.34	24.16	-20.00	35.65	12.18
5	3.47	3.22	1.67	2.09	1.30	22.18	19.70	-30.42	81.74	-16.67
6	3.59	3.75	1.51	1.61	1.85	26.41	39.41	-37.08	40.00	18.59
7	3.63	3.91	1.74	1.13	2.13	27.82	45.35	-27.50	-1.74	36.54
8	3.18	3.98	1.56	1.52	1.46	11.97	47.96	-35.00	32.17	5.41
9	3.16	3.67	1.53	1.31	1.41	11.27	36.43	-36.25	-13.91	-9.62
10	3.09	3.70	1.74	1.33	1.39	8.80	37.55	-27.50	15.65	-10.90

Area	Prex	1 Min	2 Min	3 Min	4 Min	Prex	1 Min	2 Min	3 Min	4 Min
1	143.38	142.31	125.47	74.71	109.66	+0.0	+0.0	+0.0	+0.0	+0.0

Test Name

Test Name	Results	Units	Bio. Ref. Interval
ACETYL CHOLINE RECEPTOR BINDING ANTIBODY, SERUM @ # (RIA)	6.91	nmol/L	<0.25

Interpretation

RESULT IN nmol/L	REMARKS
<0.25	Negative
0.25-0.40	Equivocal
>0.40	Positive, consistent with the diagnosis of Myasthenia gravis. Results to be clinically correlated.

Note 1. Results may be negative in the first 12 months after symptoms of MG appear or during immunosuppressant therapy
 2. Test should not be performed on patients who have recently received radioisotopes for therapeutic or diagnostic purposes
 3. Positive results are frequently found in Autoimmune liver disease
 4. Magnitude of the result is not useful for predicting severity of MG

Comments

Myasthenia gravis (MG) is characterized by weakness and easy fatigability that is relieved by rest and Anticholinesterase drugs. The weakness results from an antibody mediated loss of functional acetylcholine receptors in the post-synaptic membrane of skeletal muscle. These antibodies are not found in congenital forms of MG and are uncommon in neurologic conditions other than Acquired MG. Patients with autoimmune liver disease may also be seropositive.

Clinical Uses

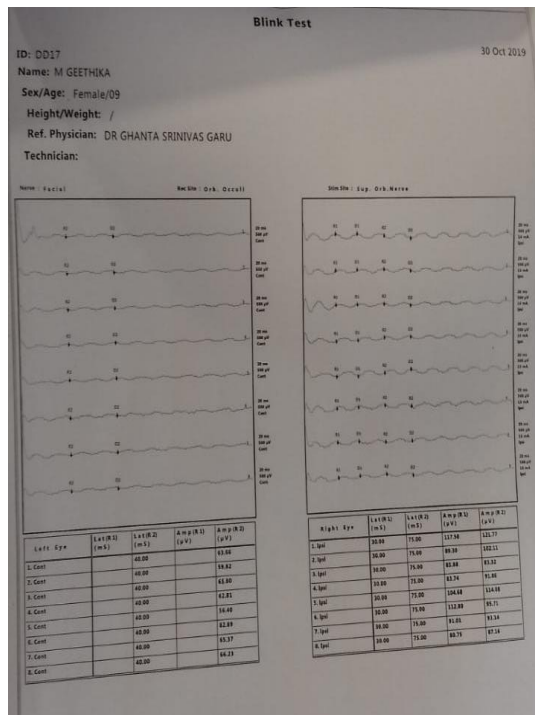

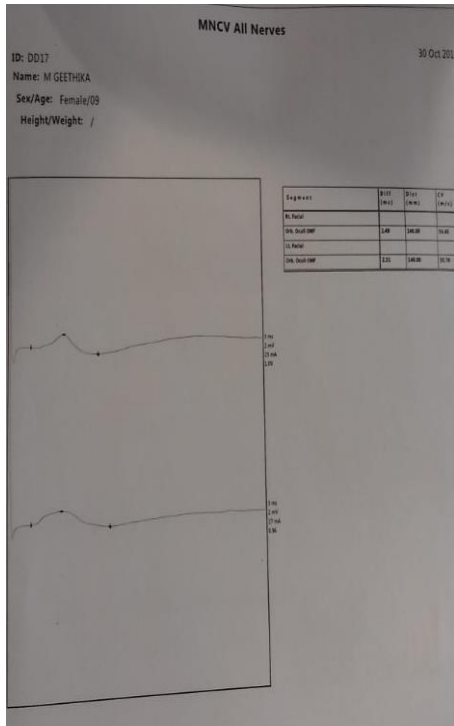
- Confirm the diagnosis of Myasthenia gravis
- Distinguish acquired disease (90% positive) from Congenital disease (negative)
- Detecting subclinical MG in patients with Thymoma or Graft versus Host disease
- Monitoring disease progression in MG or response to Immunotherapy

Rite N Kanad

Dr. Ritu Nayyar
MD, Microbiology
Consultant Microbiologist

Dr. Naveen Kanad
MD (Biochemistry)
HOD Biochem & A

End of report



They started treatment in 2015 with Ach inhibitors T.pyridostigmine 60mg (1/2) TID

T.Omnacortil 10mg(BD for 1week, 1-1/2 for next 2 weeks, 1/2-1/2 for next 2weeks,1/2 for next 2weeks); syp.Augmentin 3ml-3ml for 5days, syp.calcimax-p 5ml(TID), T.lansoprazole 15mg OD.

In 2019, this 8yr female child was admitted in another hospital. Her lab investigations were fair. she was treated with T.pyridostigmine 60mg(1/2-3/4-1/2), IV corticosteroids, antibiotics and other supportive therapy. She was clinically stable.

CONCLUSION

Myasthenia syndrome in children not uncommon but the unique in children is the inherited congenital myasthenia syndrome which is not follow autoimmune and no antibodies determined. Therefore, a precise diagnosis is important for treatment. The challenge is to differentiate this syndrome from seronegative acquired myasthenia gravis and one may need, in addition to conventional investigation, specialized microelectrode analysis of neuromuscular transmission with or without genetic test.

So here in this case the diagnosis confirmed by Acetyl Choline Receptor Binding Antibody & differentiated this syndrome by Seropositive acquired myasthenia gravis.

REFERENCES

1. Congenital myasthenia syndrome: report of four cases and brief review of literature. Publication of neurological society of India, Year: 2000, Volume: 48, Issue: 3, Page: 266-71
2. Khwaja GA, Chowdhury D, Gupta M Congenital myasthenia syndromes, Josef, *Orphanet Journal of Rare Diseases* volume 14, Article number: 57 (2019)
3. Congenital myasthenia syndrome: a case report, a.ceylan, o.tuncer, Vol.22, genetic Counselling, NO.1, 2011, PP75-78.
4. congenital myasthenia syndromes: pathogenesis, diagnosis, and treatment Vol 14, issue 4, p420-434, April 01, 2015, Dr Andrew G Engel, MD, Xin-Ming Shen, Ph.D., Duygu Selcen, MD, Steven M Sine, Ph.D., the lancet neurology
5. Engel AG: Myasthenia syndromes. In: Myology Basic and Clinical. Eds Engel AG, Franzini Armstrong C McGraw-Hill Inc, New York, 1994; 1798-1835.
6. Geer M, ScotlandM: Myasthenia gravis in the newborn. *Paediatrics*1960; 26: 101.
7. McMullenMP: Familial limb girdle myasthenia. *Brain*1966; 89: 121-132.
8. Conomy JP, Levisohn M, Fanaroff A: Familial infantile myasthenia gravis: Cause of sudden death. In young children. *J Paediatrics* 1975; 87: 428-430
9. Kaminsky HJ, Ruff RL: Congenital disorders of neuromuscular transmission. *Hospital Practice* 1992; 39: 73-96.
10. Vincent A, Newsom-Davis J, Wray D et al: Clinical and experimental observations in patients with congenital myasthenia syndromes. *Ann New York Academy of Science* 1993; 681: 451-460.
11. Engel AG, Lambert EH, Gomez MR: A new myasthenia syndrome with endplate acetylcholinesterase deficiency, small nerve terminals and reduced acetylcholine release. *Ann Neurol*1971; 1: 315-326. Back to cited text no. 8
12. Engel AG, Lambert EH, Mulder DM et al: A newly recognized congenital myasthenia syndrome attributed to a prolonged open time of the acetyl Choline induced ion channel. *Ann Neurol* 1982; 11: 553-569. Back to cited text no. 9
13. Engel AG, Walls TJ, Nagel A et al: Newly recognized congenital myasthenia syndromes. I. Congenital paucity of synaptic vesicles and reduced quantal release II. High conductance fast channel syndrome. III.

- Abnormal acetylcholine receptor (AChR) interaction with acetylcholine. IV. AChR deficiency and short channel open time. *Progress in Brain Research* 1990; 84: 125-137
14. Engel AG, Lambert EH: Congenital myasthenia syndromes. *Electro Clin Neurophysiol* 1987; 39: 91-102.
15. Andrews PI, Massey JM, Sanders DB: Acetyl Choline receptor antibodies in juvenile myasthenia gravis. *Neurology* 1993; 43: 977-982.

