



**IJPPR**

INTERNATIONAL JOURNAL OF PHARMACY & PHARMACEUTICAL RESEARCH  
An official Publication of Human Journals

ISSN 2349-7203



Human Journals

**Review Article**


August 2020 Vol.:19, Issue:1

© All rights are reserved by Monaji Sanjana Reddy

## Detailed Overview on Patent Foramen Ovale



**IJPPR**  
INTERNATIONAL JOURNAL OF PHARMACY & PHARMACEUTICAL RESEARCH  
An official Publication of Human Journals



ISSN 2349-7203

**Monaji Sanjana Reddy**

*Doctor of Pharmacy (Pharm. D), Samskruti College of  
Pharmacy  
Jawaharlal Nehru Technological University  
Hyderabad, Telangana. India.*

**Submission:** 24 July 2020  
**Accepted:** 30 July 2020  
**Published:** 30 August 2020



HUMAN JOURNALS

[www.ijppr.humanjournals.com](http://www.ijppr.humanjournals.com)

**Keywords:** Pathology of Patent Foramen Ovale, Anatomy of Patent Foramen Ovale, Symptoms of Patent Foramen Ovale, Diagnosis of Patent Foramen Ovale, Complications of Patent Foramen Ovale, Procedure of Patent Foramen Ovale

### ABSTRACT

The prolonged incomplete closure of foramen ovale leads to a condition called patent foramen ovale. The word foramen ovale is derived from Latin that means 'oval hole'. This is formed in the fetus at about the 4<sup>th</sup> week of the gestational period. Foramen ovale is an important structure that forms a bridge between the right atrium and the left atrium for the circulation of blood in the fetus. It arises to bypass the pulmonary circulation during fetal development. When the lungs become functional the foramen ovale closes progressively when left atrial pressure is higher when compared with right atrial pressure. But when the reverse happens the ovale opens and referred to as patent foramen ovale. This is seen in about 25 to 30% of individuals in an autopsy study. The presence of patent foramen ovale is common but sometimes it leads to complications. Most complicated is that it leads to stroke at any stage of life. So at that time, this foramen ovale should be treated by surgery to close the ovale. This main objective of this article is on the overall view on patent foramen ovale including a literature review.

## **INTRODUCTION:**

The foramen ovale allows blood circulation in the fetus and normally closes after 6 months to 1 year of baby's birth but in few cases, it does not close shortly after birth leading to congenital heart defects known as patent foramen ovale.(1)(2) Now this condition is being popularized due to increased incidence of patent foramen ovale into adulthood. Patent foramen ovale is a risk factor for stroke ( paradoxical thromboembolic stroke), brain stroke, heart attack, migraine with aura, an aneurism.(3)(4) This article explains in detail about patent foramen ovale.

## **ANATOMY OF FORAMEN OVALE:**

In fetal life due to the non-functioning of lungs as they are bathed in amniotic fluid the exchange of oxygenated blood occurs at the placenta and the pathway is shunted from right atrium to left atrium with help of foramen ovale. The circulation of blood according to the pressure gradient that is build up. Due to closure of pulmonary arteries there exist high pressure in right atrium and ventricles when compared with left atrium and ventricles so the blood moves down the gradient.(5) When the fetus is born, due to lung expansion by respiration the pressure in the right side of the heart decreases making the issue of foramen ovale fuse with septum is known as fossa ovalis (the closed remnant of foramen ovale).(6)

## **PATHOLOGY OF PATENT FORAMEN OVALE:**

Foramen ovale remains open due to the failure of fusion between septum primum and septum secundum. This allows the blood to flow from the right atrium to the left atrium only when the right atrial pressure increases that left atrium(example sneezing, coughing, or straining).(7)The reason for patent foramen ovale is unknown still but may be related to multifactorial inheritance.(8)Epidemiologists have explained that congenital cardiovascular diseases may arise due to cell lineage whereas molecular geneticists say that these are due to mutations and loci associated issues with familial heart and vascular defects.(9) From the study on postmortem formalin-fixed specimens the size of patent foramen ovale ranges from 1 to 19 mm (mean 4.9 mm) and the size increases each decade of life. On average, the size in the first decade is 3.4 mm while that increases to 5.8 mm in the tenth decade.(10)

## **GENES:**

This is associated with two types of genes. That include F2 (prothrombin) and apolipoprotein-C3 gene (Compliment Component 3).(7)

## **CLINICAL MANIFESTATIONS:**

In many cases, PFO (Patent Foramen Ovale) may not show any symptoms. But in very rare cases, infants may show cyanosis when the baby suffers from both PFO and another heart condition (blue tint on the skin when crying or passing stool).(11) Whereas in adults the symptoms may include breathing difficulty mainly during exercise or activity, heart palpitations, migraine headaches, fainting, high blood pressure. In severe conditions, the symptoms are stroke (transient ischemic stroke), heart failure.(12)

The signs are variable and the following word helps in easy remembering of signs:

### **BE FAST**

**B**alance: sudden loss of balance

**E**yes: sudden variation in vision

**F**ace: the fragility of face

**A**rms: sudden weakness of arms or legs

**S**peech: strenuous to speak

**T**ime: time of initiation of symptoms.(12)

## **DIAGNOSIS:**

Patent foramen ovale can be detected by echocardiogram. A transthoracic echocardiogram is mainly used to test in these sound waves that are directed towards the heart from a transducer that produces video images of the heart.



### **COLOUR FLOW DOPPLER:**

In this, the flow of blood is detected with characteristic changes and computerized colorization. When there is patent foramen ovale the flow of blood between the right atrium and left atrium can be detected in echocardiogram.(13)

### **SALINE CONTRAST ECHOCARDIOGRAPHY:**

Here the sound scattered by cells is compared for detecting patent foramen ovale. Here the gas-filled microbubbles are passed into blood vessels. When the gas-filled microbubbles pass pulmonary capillaries it indicates the absence of shunt and referred to as negative contrast echocardiogram, if the microbubbles appear in the left atrium they indicate that there is shunt between the atrium and helps to detect patent foramen ovale and referred to as positive contrast echocardiograph.(14)

### **TRANSESOPHAGEAL ECHOCARDIOGRAPHY:**

Here a thin tube is inserted into the stomach via the mouth and the esophagus helps as a transducer for ultrasound waves and gets a complete image of the heart without lungs and ribs in the image. This gives information on the size of heart, pumping of heart, blood leak through heart valves, any block, abnormalities of heart even cancer including blood clots.(15)

### **COMPLICATIONS OF PFO:**

In increasing pathological presentation of PFO, the patients include paradoxical systemic embolism; refractory hypoxemia along with right ventricular myocardium infarction; severe pulmonary disease; orthostatic oxygen desaturation in rare platypnea-orthodeoxia syndrome; neurologic decompression in divers, high altitude pilots, and astronauts; migraine headache with aura.(16) Other complications are explained in following:

1. **Relation with stroke:** Transient ischemic stroke occurs when the blood supply to the brain or spinal cord is decreased a temporary episode of neurological dysfunction occurs without causing any damage to the brain tissue. But about 25-40% are of unknown cause referred to cryptogenic strokes.(17) About 25% of ischemic strokes are cryptogenic. Nearly 50% of adults with cryptogenic stroke have PFO. About 97% of patients reduces the risk of stroke after PFO closure.(18)

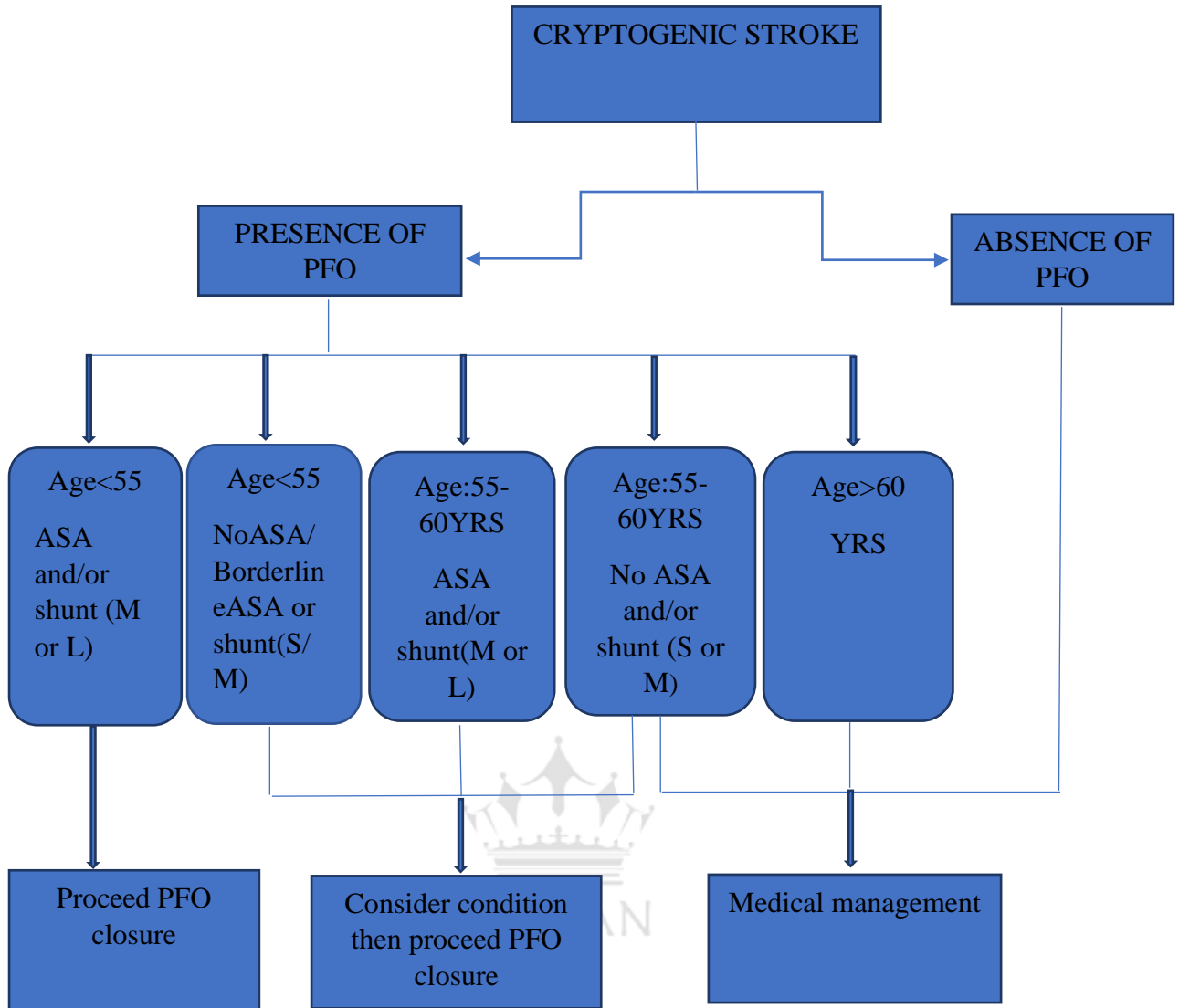
2. **Atrial septal aneurism:** There appears a bulge in a localized segment of right or left atrium. It is seen in association with congenital heart abnormalities. It is seen in about 90% of atrial septal aneurism there appears other complications include right-to-left interatrial shunt. This is detected with the help of 2-dimensional transesophageal echocardiography that appears to be moving between the right and left atrium in cardiac cycle.(19)

3. **Paradoxical embolism:** PFO can cause a paradoxical embolism. In paradoxical embolism, the embolus is carried from venous circulation to arterial circulation or from arterial circulation to venous circulation. The traveling of the emboli of thrombus can take place very easily when there appears an open due to PFO. So the condition of the patient becomes more complicated when thromboembolism occurs in association with patent foramen ovale.(20)

4. **Migraine headaches:** The number of incidents with migraine headaches mainly migraine with aura are more likely to be associated with patent foramen ovale. The reason for this according to some theories is that when the blood that should be passed to lungs for oxygenation is shunted directly to the left side of the heart and then into arteries that supply blood to various parts of the body including eyes and brain due to presence of PFO. In such cases due to this unoxygenated and some components of that blood causes the brain to interrupt and leads to migraines.(21) But according to some researchers, they demonstrate that there is no significant relation of the closure of PFO with migraine.(22) There are still ongoing clinical trials in knowing the relation of PFO closure and migraine headache.(23)

#### **MANAGEMENT:**

Management of PFO depends on the age and condition of patients with comorbid conditions. Sometimes the PFO is without symptoms that can be managed with the help of medications but there are other cardiovascular conditions then there is a need to go for closure process with surgery. The flow chart explains the management of PFO:



S: small; M: moderate; L: large

### MEDICATIONS IN MANAGING PFO:

There are no direct medications for treating PFO as it is not dangerous and also remains undiagnosed until they occur other conditions. Commonly PFO leads to the condition of stroke that is caused due to blood clots so to treat the condition of stroke there are following medications prescribed.

Anticoagulants or blood thinners are used like:

🚑 Warfarin (Coumadin™): this is normally prescribed in case of atrial fibrillation or atrial flutters, ischemic stroke. It helps in controlling heart rate and rhythm as well as anticoagulant nature that prevents clots.(24) The initial dose is 2-5 mg PO/IV (Per Oral/ Intravenous) qDay

× 2 days or 10 mg PO (Per oral) × 2 days in healthy individuals. The typical maintenance dose is 2-10 mg/day.(25) There are several other signs of problems while taking warfarin like brown coloration of urine, bloody or black stools, joint pain, blood vomiting, dizziness, headache, and severe bleeding in women during their menstrual periods. Warfarin has several interactions so care to be taken while taking warfarin.(24)

✚ Dabigatran (Pradaxa™): When the person is at a risk of using Warfarin then Dabigatran is given as an alternative. It is a short-acting medication that has a plasma life of 1 hr. the dose include 75 mg and 150 mg depending on the condition of patient.(26) This also have similar signs of problems while administering as that of Warfarin.(27)

✚ Rivaroxaban (Xarelto™): This is more used because it has fewer monitoring parameters when compared to Warfarin. At the risk of atrial fibrillation, it is given 20 mg PO qDay (Once a day).(28) It has similar signs of problems with that of warfarin.(29)

✚ Apixaban (Eliquis™): It is given at 5 mg PO BID (twice a day) per day. This should be carefully monitored during surgery and should be discontinued 48 hrs before surgery.(30) It has similar indications while using as that of warfarin.(31)

## **DISCUSSION:**

### **PFO CLOSURE:**

The Amplatzer® PFO occluder is the device that is used for closure of the hole. The device has two expandable discs with a neck that connects both discs. This is made of nickel-titanium metal alloy. The device consists of polyester mesh that occludes the flow of blood.(32)The procedure for inserting this device is through a catheter. Using the TEE (Transesophageal echocardiogram) imaging to measure the size of PFO then inserting dilator into delivery sheath and tighten rotating luer to prepare the device. Using angiography and echocardiography as guidance now insert the delivery cable into heart walls at the site and inject sterile saline first then flush the device into the wall and pull back the cable to the inert second disc and remove.(33)

## CONCLUSION:

On the whole, PFO is very difficult to be observed as it does not show any common symptoms. There are still randomized trials going on to invent new closure techniques and reduce the complications of PFO. Even there exist different strategies of closing PFO with antiplatelet therapy alone or using devices for closure are also in use.

**ABBREVIATIONS:** F2: Prothrombin; C3 gene: Complement Component 3 gene; PFO: Patent Foramen Ovale; PO/IV: Per Oral/ Intravenous route of administration; PO q Day: Per Oral Once a Day; PO BID: Per Oral Twice a Day; TEE: Transesophageal echocardiogram

**WRITING ASSISTANCE:** No others assisted in writing the article.

**FUNDING:** Not Applicable.

**CONFLICTS OF INTEREST:** None

**ETHICAL STATEMENT:** Not Applicable.

## REFERENCES:

1. Patent Foramen Ovale (PFO) (for Parents) - Nemours KidsHealth [Internet]. [cited 2020 Jul 10]. Available from: <https://kidshealth.org/en/parents/pfo.html>
2. Patent foramen ovale (Concept Id: C0016522) - MedGen - NCBI [Internet]. [cited 2020 Jul 12]. Available from: <https://www.ncbi.nlm.nih.gov/medgen/8891>
3. Patent foramen ovale: MedlinePlus Medical Encyclopedia [Internet]. [cited 2020 Jul 10]. Available from: <https://medlineplus.gov/ency/article/001113.htm>
4. Patent Foramen Ovale | Texas Heart Institute [Internet]. [cited 2020 Jul 10]. Available from: <https://www.texasheart.org/heart-health/heart-information-center/topics/patent-foramen-ovale/>
5. Blood Circulation in the Fetus and Newborn | Children's Hospital of Philadelphia [Internet]. [cited 2020 Jul 11]. Available from: <https://www.chop.edu/conditions-diseases/blood-circulation-fetus-and-newborn>
6. Yee K, Lui F. Anatomy, Thorax, Heart Foramen Ovale [Internet]. StatPearls. StatPearls Publishing; 2020 [cited 2020 Jul 11]. Available from: <http://www.ncbi.nlm.nih.gov/pubmed/31424787>
7. Patent foramen ovale pathophysiology - wikidoc [Internet]. [cited 2020 Jul 12]. Available from: [https://www.wikidoc.org/index.php/Patent\\_foramen\\_ovale\\_pathophysiology](https://www.wikidoc.org/index.php/Patent_foramen_ovale_pathophysiology)
8. Hara H, Virmani R, Ladich E, Mackey-Bojack S, Titus J, Reisman M, et al. Patent foramen ovale: current pathology, pathophysiology, and clinical status. Vol. 46, Journal of the American College of Cardiology. Elsevier; 2005. p. 1768–76.
9. Clark EB. Pathogenetic mechanisms of congenital cardiovascular malformations revisited. Semin Perinatol. 1996 Dec 1;20(6):465–72.
10. Hara H, Virmani R, Ladich E, Mackey-Bojack S, Titus J, Reisman M, et al. Patent foramen ovale: current pathology, pathophysiology, and clinical status [Internet]. Vol. 46, Journal of the American College of Cardiology. Journal of the American College of Cardiology; 2005 [cited 2020 Jul 12]. p. 1768–76. Available from: <https://www.onlinejacc.org/content/46/9/1768>
11. Patent Foramen Ovale: Symptoms, Diagnosis, and Treatments [Internet]. [cited 2020 Jul 13]. Available from: <https://www.healthline.com/health/patent-foramen-ovale#symptoms>



12. Atrial Septal Defect and Patent Foramen Ovale | Heart Care | Intermountain Healthcare [Internet]. [cited 2020 Jul 14]. Available from: <https://intermountainhealthcare.org/services/heart-care/conditions/atrial-septal-defect/>
13. Patent foramen ovale - Diagnosis and treatment - Mayo Clinic [Internet]. [cited 2020 Jul 14]. Available from: <https://www.mayoclinic.org/diseases-conditions/patent-foramen-ovale/diagnosis-treatment/drc-20353491>
14. Gupta SK, Shetkar SS, Ramakrishnan S, Kothari SS. Saline Contrast Echocardiography in the Era of Multimodality Imaging-Importance of “*Bubbling It Right.*” Echocardiography [Internet]. 2015 Nov 1 [cited 2020 Jul 14];32(11):1707–19. Available from: <http://doi.wiley.com/10.1111/echo.13035>
15. Transesophageal Echocardiography | Mercy [Internet]. [cited 2020 Jul 15]. Available from: <https://www.mercy.net/service/transesophageal-echocardiography/>
16. Fazio G, Ferro G, Barbaro G, Fattouch K, Ferrara F, Novo G, et al. Patent Foramen Ovale and Thromboembolic Complications. *Curr Pharm Des* [Internet]. 2010 Dec 1 [cited 2020 Jul 17];16(31):3497–502. Available from: <https://pubmed.ncbi.nlm.nih.gov/20858189/>
17. Patent Foramen Ovale | JACC: Journal of the American College of Cardiology [Internet]. [cited 2020 Jul 15]. Available from: <https://www.onlinejacc.org/content/59/19/1665>
18. Stroke Prevention Treatments | cryptogenicstroke.com [Internet]. [cited 2020 Jul 15]. Available from: <https://www.cryptogenicstroke.com/int/hcp/>
19. Chidambaram M, Mink S, Sharma S. Atrial septal aneurysm with right-to-left interatrial shunting. *Texas Hear Inst J* [Internet]. 2003 [cited 2020 Jul 17];30(1):68–70. Available from: <http://www.ncbi.nlm.nih.gov/pubmed/12638676>
20. Paradoxical embolism - Wikipedia [Internet]. [cited 2020 Jul 18]. Available from: [https://en.wikipedia.org/wiki/Paradoxical\\_embolism](https://en.wikipedia.org/wiki/Paradoxical_embolism)
21. Patent Foramen Ovale (PFO) and Migraine | American Migraine Foundation [Internet]. [cited 2020 Jul 18]. Available from: <https://americanmigrainefoundation.org/resource-library/patent-foramen-ovale-pfo-migraine/>
22. Dowson A, Mullen MJ, Peatfield R, Muir K, Khan AA, Wells C, et al. Migraine intervention with STARFlex technology (MIST) trial: A prospective, multicenter, double-blind, sham-controlled trial to evaluate the effectiveness of patent foramen ovale closure with STARFlex septal repair implant to resolve refractory migraine headache. *Circulation* [Internet]. 2008 Mar [cited 2020 Jul 18];117(11):1397–404. Available from: <https://pubmed.ncbi.nlm.nih.gov/18316488/>
23. PFO - Patient's Guide to Holes in the Heart - MyHeart [Internet]. [cited 2020 Jul 18]. Available from: <https://myheart.net/articles/patent-foramen-ovale-pfo/>
24. About Warfarin (Coumadin) [Internet]. [cited 2020 Jul 22]. Available from: <http://www.secondscount.org/heart-condition-centers/info-detail-2/about-warfarin-coumadin#.XxhAjJ4zZPY>
25. Coumadin, Jantoven (warfarin) dosing, indications, interactions, adverse effects, and more [Internet]. [cited 2020 Jul 22]. Available from: <https://reference.medscape.com/drug/coumadin-jantoven-warfarin-342182>
26. Pradaxa (dabigatran) dosing, indications, interactions, adverse effects, and more [Internet]. [cited 2020 Jul 22]. Available from: <https://reference.medscape.com/drug/pradaxa-dabigatran-342135#0>
27. About Dabigatran (Pradaxa) [Internet]. [cited 2020 Jul 22]. Available from: <http://www.secondscount.org/heart-condition-centers/info-detail-2/about-dabigatran-pradaxa#.XxhFUJ4zZPY>
28. Xarelto (rivaroxaban) dosing, indications, interactions, adverse effects, and more [Internet]. [cited 2020 Jul 22]. Available from: <https://reference.medscape.com/drug/xarelto-rivaroxaban-999670>
29. About Rivaroxaban (Xarelto) [Internet]. [cited 2020 Jul 22]. Available from: <http://www.secondscount.org/heart-condition-centers/info-detail-2/about-rivaroxaban-xarelto#.XxhHB54zZPY>
30. Eliquis (apixaban) dosing, indications, interactions, adverse effects, and more [Internet]. [cited 2020 Jul 22]. Available from: <https://reference.medscape.com/drug/eliquis-apixaban-999805>
31. About Apixaban (Eliquis) [Internet]. [cited 2020 Jul 22]. Available from: <http://www.secondscount.org/heart-condition-centers/info-detail-2/about-apixaban-eliquis#.XxhIP54zZPY>
32. Closing a Patent Foramen Ovale, Catheter-Based Procedures, PFO Closure Devices [Internet]. [cited 2020 Jul 22]. Available from: <https://my.clevelandclinic.org/health/treatments/11627-patent-foramen-ovale-pfo--catheter-based-procedures>
33. Amplatzer [Internet]. [cited 2020 Jul 22]. Available from: <https://www.fda.gov/media/97980/download>

<p><i>Image</i> <i>Author -1</i></p>	<p><i>Author Name – Corresponding Author</i> <b><i>M. Sanjana Reddy</i></b> <i>Department of Pharmacy Practice, Pharm. D</i> <i>Samskruti College of Pharmacy,</i> <i>Jawaharlal Nehru Technological University, Hyderabad</i> <i>India.</i></p>
--	--

